

## 선천성 이첨판성 폐동맥 판막

영남대학교 의과대학 순환기내과학교실,<sup>1</sup> 연세대학교 의과대학 심장혈관병원 심장내과<sup>2</sup>  
 1. 2. 2. 2. 2

### Isolated Bicuspid Pulmonic Valve

Geuru Hong, MD<sup>1</sup>, Seokmin Kang, MD<sup>2</sup>, Jong-Won Ha, MD<sup>2</sup>,  
 Se-Joong Rim, MD<sup>2</sup> and Namsik Chung, MD<sup>2</sup>

<sup>1</sup>Division of Cardiology, Department of Internal Medicine, Yeungnam University, Daegu, Korea

<sup>2</sup>Cardiology Division, Yonsei Cardiovascular Hospital, Yonsei University College of Medicine, Seoul, Korea

(Fig. 2),  
 , Fallot 4  
 (tetralogy of Fallot),

7%

가

중심 단어 :

#### REFERENCES

McAleer E, Kort S, Rosenzweig BP, Katz ES, Tunick PA,  
 Phoon CK, Kronzon I. Unusual echocardiographic views of  
 bicuspid and tricuspid pulmonic valves. *J Am Soc Echocar-*  
*diography* 2001;14:1036-8.

67

(Fig. 1), (main pulmonary artery)

: 2003 5 30

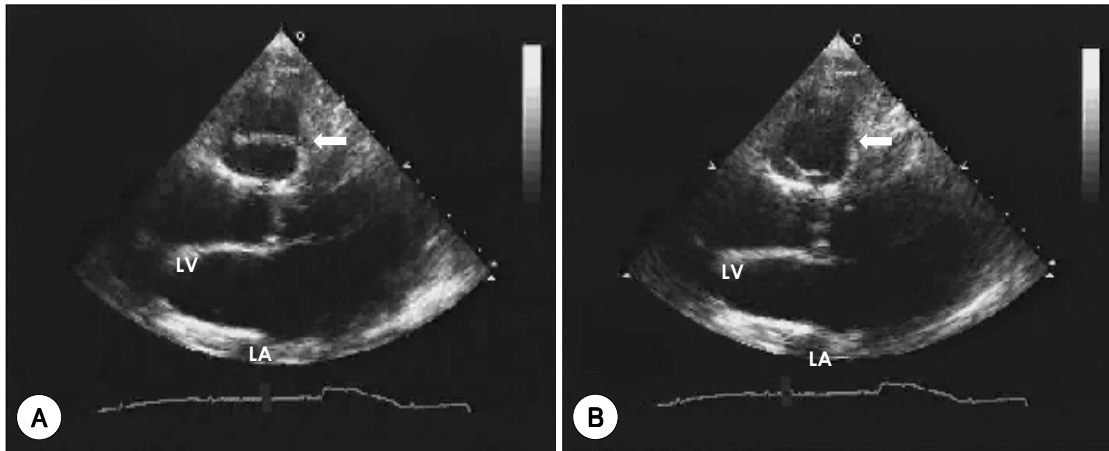
: 2003 6 15

: , 120 - 752

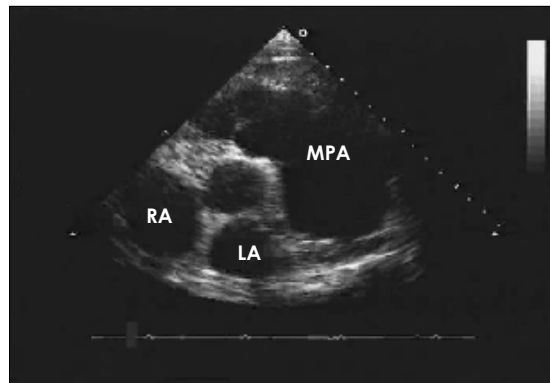
134

: (02) 361 - 7075 · : (02) 393 - 2041

E - mail : namsikc@yumc.yonsei.ac.kr



**Fig. 1.** Transthoracic echocardiographic parasternal long axis view showing bicuspid pulmonic valve (arrow) at diastole (A) and systole (B).



**Fig. 2.** Transthoracic echocardiographic parasternal short axis view showing dilated main pulmonary artery.