

Paratracheal Air Cysts: Sonographic Findings in Two Cases

Young-Jin Kim, MD¹
Eun-Kyung Kim, MD¹
Jinna Kim, MD¹
Cheong Soo Park, MD²

We report two cases of paratracheal air cyst discovered incidentally at neck ultrasonography and confirmed at CT. The cysts were located at the inferoposterior aspect of the right lobe of the thyroid. Ultrasonography revealed an ill-defined hypoechoic mass containing hyperechoic foci which mimicked calcifications. Neck CT confirmed the presence of an ill-defined air pocket which communicated with the trachea through a slit.

Paratracheal air cyst is a rarely described lesion, and its pathologic nature is not clearly proven (1–4). Previous reports state that the cyst was identified at routine chest radiography or chest CT (1, 2); the sonographic findings have not, however, been described. In this report, we present two cases of paratracheal air cyst with peculiar sonographic findings.

CASE REPORTS

Case 1

A 43-year-old woman underwent neck sonography as part of a routine medical checkup. Six years earlier she had received a renal transplant, and the kidney involved had been functioning well up to the time of the checkup.

Neck ultrasonography revealed a 2.9×1.4 -cm hypoechoic mass at the inferoposterior aspect of the right lobe of the thyroid (Figs. 1A, B). The lesion, located outside the thyroid capsule, had an ill-demarcated margin and contained multiple hyperechoic foci which appeared to be small calcifications. The thyroid gland was normal in echogenicity and size, and no focal lesion was observed. Cervical lymphadenopathy was absent.

Subsequently, on the basis of the sonographic findings, a tumor of the right parathyroid gland was suspected, and needle aspiration biopsy (NAB) was planned. Further sonography suggested that the hyperechogenic foci were mobile. To rule out Zenker's diverticulum, esophagography was also performed, and the findings were negative.

For further evaluation, neck CT scans were obtained, and an unusual air pocket was found on the right side of the trachea. It had an irregular wall (Fig. 1C), and multiplanar reformatted imaging showed that a slit-like structure linked it with the trachea (Fig. 1D). The findings of chest radiography were normal, however. After reviewing all the above findings, a paratracheal air cyst was diagnosed.

Case 2

A 65-year-old man presented with anterior neck pain. Sonography indicated that the thyroid gland was normal, but at the inferoposterior aspect of its right lobe, an ill-defined hypoechoic mass was discovered (Figs. 2A, B). The lesion contained multiple

Index terms:
Trachea, cysts
Trachea, US
Trachea, CT

Korean J Radiol 2003; 4: 136-139
Received September 9, 2002; accepted
after revision March 10, 2003.

¹Department of Diagnostic Radiology, Research Institute of Radiological Science, Seoul, Korea; ²Department of General Surgery, Severance Hospital, Yonsei University College of Medicine, Yonsei University College of Medicine, 134 Shinchon-dong, Seodaemun-gu, Seoul 120-752, Korea.

Address reprint requests to:
Eun-Kyung Kim, MD, Department of Diagnostic Radiology, Research Institute of Radiological Science, Severance Hospital, Yonsei University College of Medicine, 134 Shinchon-dong, Seodaemun-gu, Seoul 120-752, Korea.
Telephone: (822) 361-5837
Fax: (822) 393-3035
e-mail: ekkim@yumc.yonsei.ac.kr

Sonographic Findings of Paratracheal Air Cysts in Two Cases

echogenic foci which appeared to be mobile. Esophagography revealed no evidence of esophageal diverticulum, but neck CT demonstrated an ill-defined air pocket, which communicated with the trachea (Figs. 2C, D). Chest radiographs revealed mild emphysematous change but did not depict the air pocket in the right lower neck region.

DISCUSSION

A paratracheal air cyst is histopathologically diverse. In surgically confirmed cases, pathologic diagnoses of these cysts vary (tracheal diverticulum, or lymphoepithelial or bronchogenic cyst), but all are lined by ciliated columnar epithelium and communicate with the trachea (1–4).

The differential diagnosis of a paratracheal air collection includes pharyngocele, esophageal diverticulum, laryngocele, apical hernia of the lung, and apical paraseptal blebs or bullae (1, 2). Because of the reverberation artifact at ultrasonography, Zenker's diverticulum may be seen as a mass with hyperechoic foci, mimicking a thyroid nodule, but the shape of the mass changes as the patient swallows, and the hyperechoic foci are mobile (5, 6). A barium swallow study is used to confirm Zenker's diverticulum and pharyngocele. Laryngocele can be identified at CT as abnormal dilatation of the saccule of the laryngeal ventricle (7), and CT also shows that apical hernia of the lung is contiguous with the remainder of the lung. At chest radiography, the hernia tends to enlarge on forced expiration and

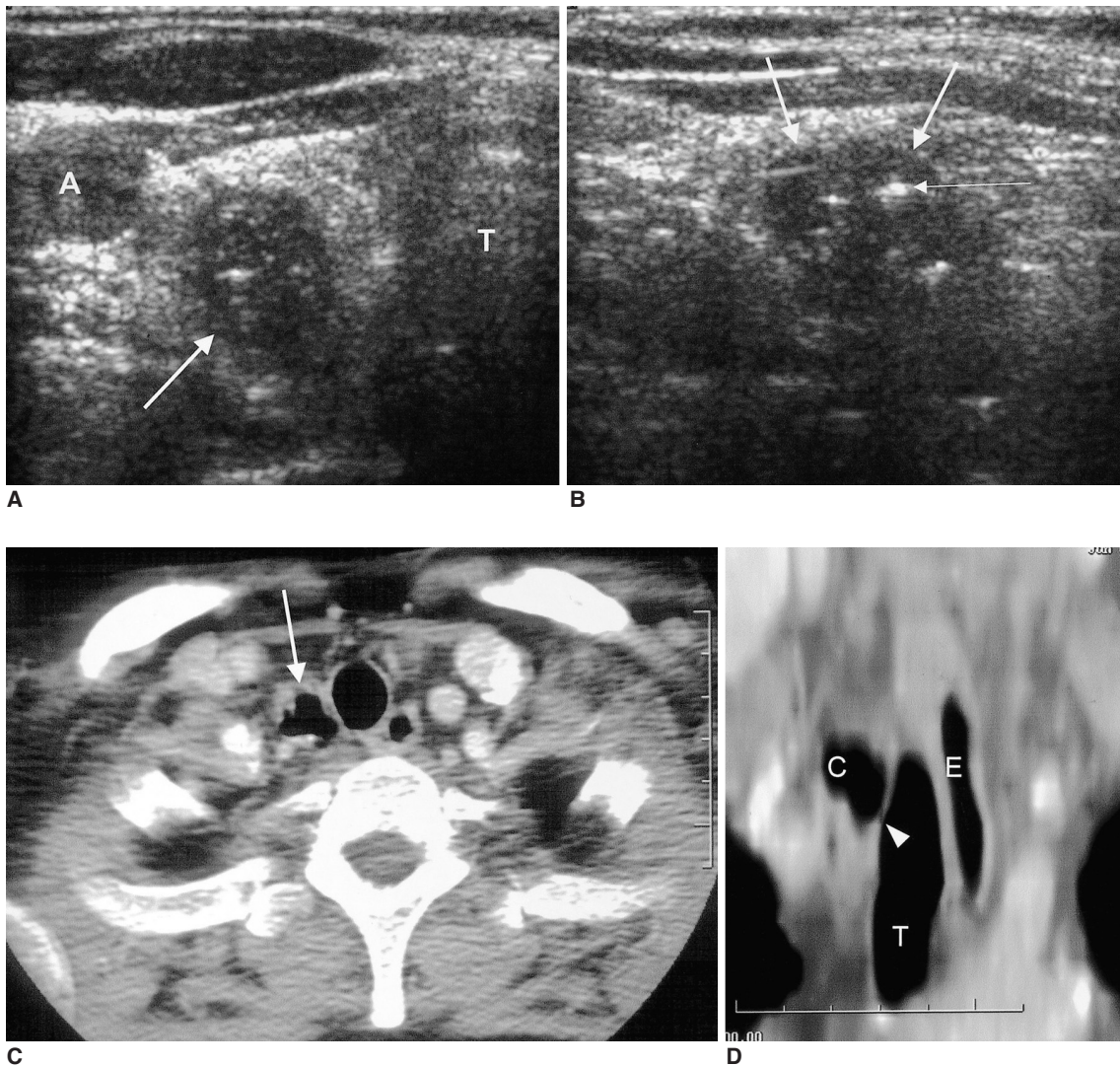


Fig. 1. A 43-year-old woman who underwent a routine medical checkup.
A, B. Transverse (**A**) and longitudinal (**B**) sonograms of the neck depict a 2.9 x 1.4 - cm hypoechoic mass (thick arrows) with multiple hyperechoic foci (thin arrow) at the inferoposterior aspect of the right lobe of the thyroid gland.
C. Neck CT shows an air-filled cyst (arrow) with an irregular wall to the right of the trachea.
D. Reformatted coronal CT image depicts slit-like communication (arrowhead) between the trachea and the air cyst. (A=right common carotid artery, C=paratracheal air cyst, E=esophagus, T=trachea)

shrink on inspiration (8). Apical paraseptal blebs or bullae, which are air cysts within the lung, can be recognized on CT scans.

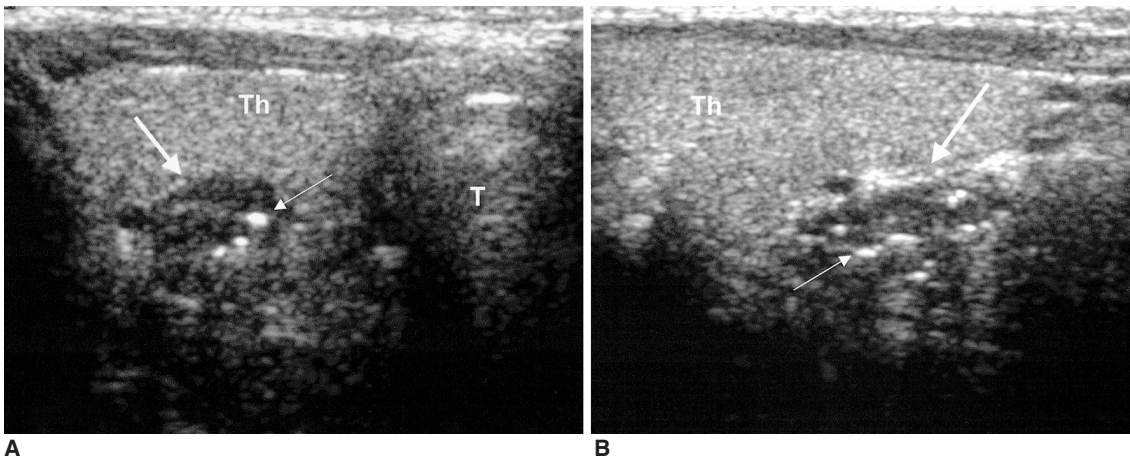
In most previously reported cases, paratracheal air cysts were identified at routine chest radiography and CT, and were located at the right posterolateral aspect of the trachea at the level of the T1-T2 vertebral body (1–4). Goo et al. (4) reported that if a right paratracheal air cyst was observed at CT, this could be a sign of obstructive lung disease, clinically, and of the presence of emphysema, radiologically.

At initial ultrasonography, we misdiagnosed the paratracheal air cyst as a calcified parathyroid mass. Surprisingly, the cyst appeared as a hypoechoic mass-like lesion at ultrasonography, though CT revealed no fluid density within it.

We constructed a paratracheal air cyst model by trapping a balloon between slices of pork (Figs. 3A, B), and ultrasonography of the model demonstrated a hypoechoic mass with multiple echogenic foci (Fig. 3C). This outcome was

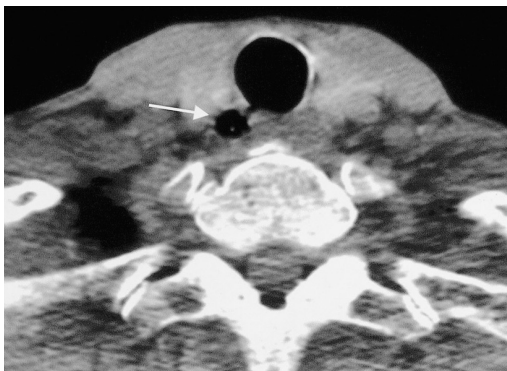probably due to the strong reflection of the ultrasound beam from the anterior wall of the balloon, and the multiple echogenic foci detected within the mass may be due to reverberation artifact. This phantom model explains why the paratracheal air cyst was seen as a hypoechoic mass containing hyperechoic foci. Moreover, compression by the sonographic transducer distorts the wall, making it more irregular, and this invokes artifacts from many different directions. As a result, the shape of the hyperechoic foci is more irregular.

In conclusion, when sonography depicts a mass-like lesion containing hyperechoic foci at the right inferoposterior aspect of the thyroid gland and to the right of the trachea, the possibility of a paratracheal air cyst should be considered. CT may help disclose the nature of the lesion before performing an invasive procedure such as NAB.

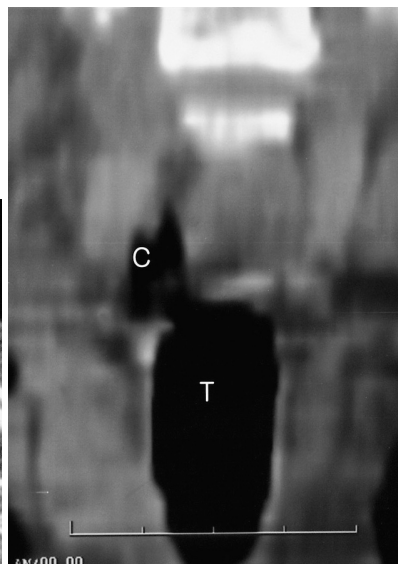


A

B



C



D

Fig. 2. A 65-year-old man who presented with anterior neck pain.

A, B. Transverse (**A**) and longitudinal (**B**) sonograms of the neck reveal a 2.5×1.1 -cm hypoechoic mass (thick arrows) with multiple hyperechoic foci (thin arrows) at the inferoposterior aspect of the right lobe of the thyroid gland.

C. Neck CT shows an air cyst (arrow) to the right of the trachea, with slit-like communication between it and the trachea.

D. Reformatted coronal CT image reveals the presence of an air pocket to the right of the trachea.

(C=paratracheal air cyst, E=esophagus, T=trachea, Th=right lobe of the thyroid gland)

Sonographic Findings of Paratracheal Air Cysts in Two Cases

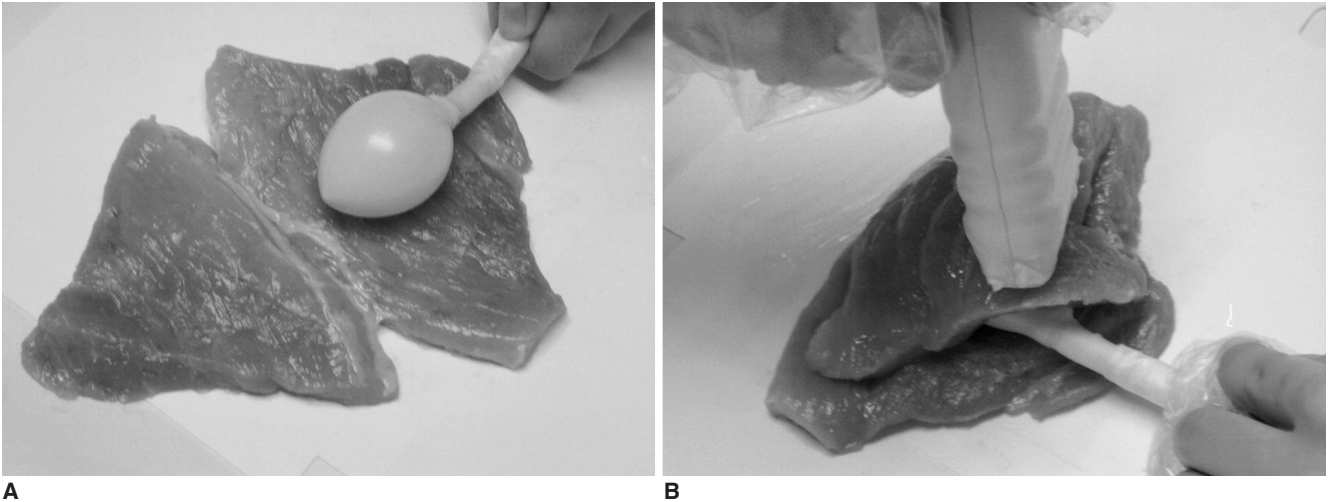
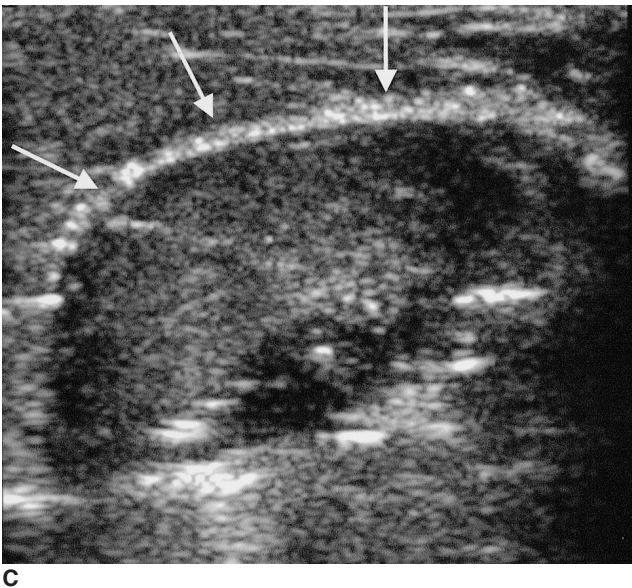


Fig. 3. A phantom model made with pork and a balloon.
A, B. A small balloon connected to a syringe was placed between two slices of pork, and ultrasonography was performed.
C. The balloon is depicted as a hypoechoic mass (arrows) with an echogenic wall. Within it, multiple hyperechoic foci are observed.



References

1. Tanaka H, Mori Y, Kurokawa K, Abe S. Paratracheal air cysts communicating with the trachea: CT findings. *J Thorac Imaging* 1997;12:38-40
2. Goo JM, Im JG, Ahn JM, et al. Right paratracheal air cysts in the thoracic inlet: clinical and radiologic significance. *AJR Am J Roentgenol* 1999;173:65-70
3. Infante M, Mattavelli F, Valente M, et al. Tracheal diverticulum: a rare cause and consequence of chronic cough. *Eur J Surg* 1994;160:315-316
4. Tanaka H, Igarashi T, Teramoto S, Yoshida U, Abe S. Lymphoepithelial cysts in the mediastinum with an opening to the trachea. *Respiration* 1995;62:110-113
5. Kumar A, Aggarwal S, Pham DH. Pharyngoesophageal (Zenker's) diverticulum mimicking thyroid nodule on ultrasonography: report of two cases. *J Ultrasound Med* 1994;13:319-322
6. Kim J, Kim YJ, Kim EK, Park CS. Incidentally found pharyngoesophageal diverticulum on ultrasonography. *Yonsei Med J* 2002;43:271-273
7. Glazer HS, Mauro MA, Aronberg DJ, et al. Computed tomography of laryngoceles. *AJR Am J Roentgenol* 1983;140:549-552
8. McAdams HP, Gordon DS, White CS. Apical lung hernia: radiologic findings in six cases. *AJR Am J Roentgenol* 1996;167:927-930