

Burkitt's Lymphoma Representing Periportal Infiltrating Mass on CT

Kae Young Park¹, Jeong-Sik Yu¹, Sang-Wook Yoon², Mi-Sook Park¹, Ja Seung Koo³, and Ki Whang Kim⁴

¹Department of Diagnostic Radiology, Yongdong Severance Hospital, Yonsei University College of Medicine, Seoul, Korea;

²Department of Diagnostic Radiology, Bundang CHA General Hospital, Pochon CHA University College of Medicine, Kyonggi-do, Korea;

³Department of Diagnostic Radiology, ⁴Diagnostic Pathology, Yonsei University College of Medicine, Seoul, Korea.

Imaging findings of secondary hepatic lymphoma have been reported as variable, ranging from single or multiple small nodules to diffuse infiltrative tumor patterns.

We here present a rare case report concerning aggressive B cells, secondary Burkitt's lymphoma in non-AIDS demonstrating a surprising periportal lymphoma infiltration, without upper abdominal lymphadenopathy or splenomegaly on the sonography and CT scans. Clinically, the case was characterized by atypical and highly aggressive course, with the patient presenting an abruptly developed obstructive jaundice with rapidly deteriorating hepatic function that could be indicative of cholestatic hepatitis, which differs in its clinical manifestations from hepatic lymphoma without functional deterioration in respect of its non-tissue destructive growth pattern.

We suggest that hepatic lymphoma can sometimes be consistent with periportal infiltrating homogeneous mass, with no lymphadenopathy or splenomegaly on the imaging examination, with a predictable aggressive clinical course of the disease and poor prognosis.

Key Words: Abdomen, neoplasm, hepatic lymphoma, diagnosis, systemic lymphoma

INTRODUCTION

Liver, as a part of the reticuloendothelial system, is commonly affected by lymphoma. The hepatic involvement of malignant lymphoma,

either primary or secondary, has been described as a diffuse parenchymal infiltration or localized mass detected by various imaging examination modalities. We report a case of high grade B cell, Burkitt's lymphoma representing a unique periportal infiltrating mass, with an aggressive clinical course.

CASE REPORT

A 60-year-old woman presented with a 1-week history of mild fever, cough, abundant sputum secretion, and sore throat. One month earlier, she had a non-tender, firm, fixed neck mass detected that by the contrast-enhanced CT was revealed as a 5 × 4 cm sized low attenuation mass lesion, with thin irregular rim enhancement (not shown). The first impression based on the image examination in respect of the neck lesion reportedly could be compatible with tuberculous lymphadenopathy with extensive caseous necrosis or necrotic metastatic lymphadenopathy from unknown malignant tumors. The mass lesion was described as a non-specific necrotizing lymphadenitis based on excision biopsy. At that time, there were no abnormal laboratory findings in respect of the patient's peripheral blood.

On day 9 on admission, a rapid deterioration of laboratory findings was noted as compared to the findings from day 1: AST/ALT, from 79/82 to 330/370 (normal ranges: 13-37/7-43 IU/L); total/direct bilirubin, from 0.5/no checked to 4.4/3.7 (0.2-1.3/0.1-0.4 mg/dl); alkaline phosphatase, from

Received November 7, 2003

Accepted January 15, 2004

Reprint address: requests to Dr. Ki Whang Kim, Department of Diagnostic Radiology, Yonsei University College of Medicine, 134 Shinchon-dong, Seodaemun-gu, Seoul 120-752, Korea. Tel: 82-2-361-5829, Fax: 82-2-393-3035, E-mail: kwkimyd@yumc.yonsei.ac.kr

103 to 505 (42-117 IU/L); and LDH presenting a marker of a rapid lymphocyte destruction in the result of an infectious process or lymphoproliferative disease, from 2630 to 5920 (225-455 IU/L). All of the serologic tests for EBV Ab EA IgM/EA IgG/EANA IgG were positive, suggesting a pattern typical of EBV reactivation. The serologic test for the human immunodeficiency virus (HIV) was negative.

On the abdominal sonography made on day 9 for evaluation of the possibility of obstructive jaundice, a homogeneous low echoic infiltrating lesion encasing the portal system was found; it was newly developed as compared to the previous sonogram taken on the admission day. But, there was no obstructive mass at porta hepatis or bile duct dilatation (Fig. 1A). On the same day, the periportal encircling and infiltrating hypodense mass was also demonstrated on the contrast-enhanced abdominal CT scan, without regional lymphadenopathy or splenomegaly (Fig. 1B).

Gastroscopy assisted biopsies were performed targeting to the incidentally detected several nodular elevations in the stomach and duodenum (not shown). The histopathologic examination of the lesions revealed high-grade B-cell, Burkitt's lymphoma (Fig. 2). The histopathologic re-evaluation was compared with previously excised cervical lymphadenopathy, and there was an additional pathologic feature that peripherally scattered karyorrhexis of lymphocytes suggested the

possibility of an extensive lymphoma necrosis.

The bone marrow biopsy with the immunostain revealed an aggressive lymphocytes infiltration with nearly total, more than 90%, necrosis and positive monoclonal antibody to CD-20, consistent with Burkitt's lymphoma in the leukemic phase. After the systemic chemotherapy, the periportal infiltrating mass disappeared on the follow-up sonography, and the serum concentration of the hepatic enzymes normalized. The

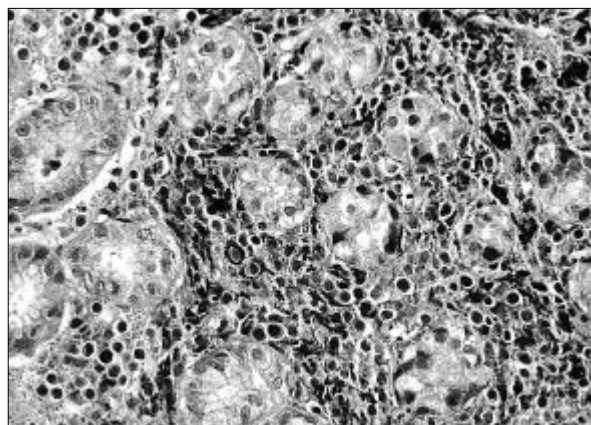


Fig. 2. Photomicrograph of the histopathologic specimen from the stomach lesion reveals malignant lymphoma, B-cell type, high-grade with plasmacytoid differentiation (H&E stain, $\times 100$). In the later performed bone marrow biopsy with the immuno-stain (not shown), it reveals an aggressive lymphocyte infiltration with nearly total necrosis and positive monoclonal antibody to CD-20, consistent with Burkitt's lymphoma in the leukemic phase.

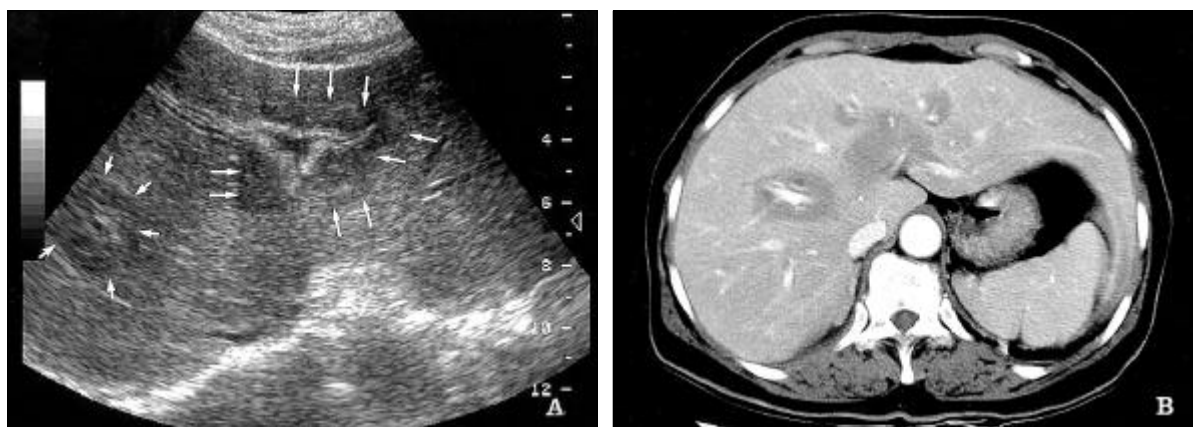


Fig. 1. A. Abdominal sonography for evaluation of the possibility of obstructive jaundice shows an abruptly developed, slightly irregular, expanded, homogeneous, low echoic mass (arrows) encasing the portal system, without signs of the bile duct obstruction, which is the contiguous lesion in other images (not shown), as compared to the last sonography made nine days before. B. Contrast-enhanced abdominal CT scan performed just after the abdominal sonography shows the periportal encircling, homogeneously hypodense mass, with no regional lymphadenopathy or splenomegaly.

serum level of alkaline phosphatase, bilirubin, and LDH markedly decreased. Depending on the clinical and follow-up imaging findings, the periportal infiltrating mass was regarded as a manifestation of lymphomatous infiltration, despite failure to performed a direct histopathologic investigation. The patient expired on day 62 after the pathologic diagnosis due to the post-chemotherapy pancytopenic sepsis.

DISCUSSION

Although primary hepatic lymphoma is a very rare condition, the secondary involvement of the liver is relatively common at staging laparotomy in 3-14% and at autopsy in 50-80% of patients with Hodgkin's or non-Hodgkin's lymphomas.^{1,2}

Pathologically, the hepatic involvement in case of lymphoma usually is noted as multifocal, within the portal tract, predominantly presenting a diffuse infiltration or contained multifocal scattered foci of the tumor. These situations are difficult to evaluate with sonography or CT scan, although larger nodules may sometimes be recognized as discrete hypoechoic or hypodense areas.¹

Some investigators have reported that the primary type of the disease usually is presented as a well defined single large mass characterized by large cell lymphoma, usually of B-cell immunophenotype, whereas the secondary type can be more variable, ranging from single or multiple small nodules to diffuse infiltrative disease.^{2,3} The radiologic examination concerning a gross periportal tumor infiltration is very rare, and it has been reported in the patients with juvenile chronic myelogenous leukemia and diffuse non-Hodgkin's lymphoma (natural killer cell and Burkitt type).^{1,4} However, those cases noted were concomitant with upper abdominal lymphadenopathy, including the hilar area. Only one case of the periportal mass, documented as Burkitt's lymphoma, has been reported without perihilar lymphadenopathy, in a HIV positive patient.¹ Our patient is also a very rare case report that shows a surprising periportal infiltrating Burkitt's lymphoma, without perihilar lymphadenopathy, but unrelated to AIDS.

The infiltrating homogeneous mass along the periportal tract, in our case, showed hypoechoic or hypodense lesion on sonography and CT scan, respectively, with slightly irregular expanded contour. These radiologic findings should be differentiated from the "periportal halo" or "periportal tracking", which is distinguished by circumferential thin halos of fluid or low attenuation around the portal vein branches, developed due to pathologically proved various causes within the Glisson's capsule: blood, lymphedema associated with impaired lymphatic drainage, secondary to transplantation or tumor or portal lymphadenopathy, periportal inflammation, and bile duct proliferation.⁵

In the review of literatures on this pathology, low-grade hepatic lymphoma is presented with a conspicuous portal distribution of the tumor infiltration in a multicentric fashion, and it appears compact and "nodule" even in patients with diffuse disease. Otherwise, the aggressive lymphoma shows commonly diffuse hepatomegaly due to the widespread portal infiltration through the liver. Furthermore, it often grows as expansive nodules compressing rather than diffusely infiltrating the contiguous tissues. Some cases with sinusoidal infiltration and focal parenchymal invasion could produce very unusual lymphoma - induced hepatobiliary dysfunctions, simulating hepatitis.^{6,7} Up to 40% of aggressive B-cell lymphomas, including diffuse large cell, Burkitt, and lymphoblastic types, are initially diagnosed in various extranodal locations, such as mediastinum, breast, bone, skin, and body cavities as well as the rare case with extranodal intravascular lymphomatosis.

Our case revealed a radiologically detectable periportal tumor infiltration, without perihilar lymphadenopathy from the systemic hepatic lymphoma, pathologically proven Burkitt's lymphoma in the leukemic phase with bone marrow involvement. The histopathology that revealed nearly total, more than 90%, necrosis of the bone marrow suggests a highly aggressive and rapidly proliferated growth pattern. The clinical manifestation also included highly aggressive and atypical features that showed a rapid progression of cholestatic hepatitis with the liver failure. In contrast to common consideration for the non-

destructive and non-obstructive lymphoma growth, the deterioration of the hepatic function with the obstructive jaundice, in our case, may be possible due to the aggressive tumor infiltration associated loss of the periportal liver cells and variable damage of the small bile ducts.⁸ Because of the non-specificity of the initial histopathologic report of the cervical necrotizing lymphadenopathy, there was a confusion in the imaging diagnosis in respect of this unusual clinical presentation of the hepatobiliary disease; in particular, it showed no intra-abdominal lymphadenopathy or splenomegaly on the CT scan.

The mechanism accounting for the periportal spread of lymphoma without perihilar lymphadenopathy is still obscure and impenetrable. The hepatic lymph originates mainly from the sinusoids and drains through the collecting vessels in more than 80% that run along the portal veins and the bile ducts downstream to the liver hilum, and, further into the cisterna chyli. As to the remaining route, it drains through the lymphatic vessels that accompany the hepatic veins directly into the thoracic duct or retrosternal lymphatic channel.⁹ So, we suggest that the mechanism of the periportal tumor infiltration, without perihilar lymphadenopathy in the secondary hepatic lymphoma, is, first, a tendency of the extranodal hepatic involvement by the aggressive lymphoma and, second, a tumor growth pattern and rate presenting as a widespread periportal infiltration in multicentric fashion through the entire liver, with a rapid tumor growth, not yet demonstrating a regional lymph node involve-

ment.

To sum up, we report a rare case of Burkitt's lymphoma in a non-AIDS patient representing a unique periportal infiltrating mass characterized by the lack of perihilar lymphadenopathy on the CT scan, with an aggressive clinical course.

REFERENCES

1. Coakley FV, O'Reilly EM, Schwartz LH, Panicek DM, Castellino RA. Non-Hodgkin lymphoma as a cause of intrahepatic periportal low attenuation on CT. *JCAT* 1997;21:726-8.
2. Soyer P, Beers BV, France TT, Grandin C, Kazerouni F, Barge J, et al. Hodgkin's and non-Hodgkin's hepatic lymphoma: sonographic findings. *Abdom Imaging* 1993;18:339-43.
3. Gazelle GS, Lee MJ, Hahn PF, Goldberg MA, Rafaat N, Mueller PR. US, CT, and MRI of primary and secondary liver lymphoma. *JCAT* 1994;18:412-5.
4. Siegel MJ, Herman TE. Periportal low attenuation at CT in childhood. *Radiology* 1992;183:685-8.
5. Lawson TL, Thorsen MK, Erickson SJ, Perret RS, Quiroz FA, Foley WD. Periportal halo: a CT sign of liver disease. *Abdom Imaging* 1993;18:42-6.
6. Jaffe ES. Malignant lymphomas: pathology of hepatic involvement. *Semin Liver Dis* 1987;7:257-68.
7. Harris AC, Ben-Ezra JM, Contos MJ, Kornstein MJ. Malignant lymphoma can present as hepatobiliary disease. *Cancer* 1996;78:2011-9.
8. Lefkowitz JH, Falkow S, Whitlock RT. Hepatic Hodgkin's disease simulating cholestatic hepatitis with liver failure. *Arch Pathol Lab Med* 1985;109:424-6.
9. Diemer EE. Lymphatic anatomy. In: Herlinger H, Lunderquist A, Wallace S, editors. *Clinical radiology of the liver*. New York: Marcel Dekker;1983. p.55-63.