

# Solitary Fibrous Tumor of the Urinary Bladder

Se Hoon Kim<sup>1</sup>, Kyung Bin Cha<sup>2</sup>, Young Deuk Choi<sup>2</sup>, and Nam Hoon Cho<sup>1</sup>

Departments of <sup>1</sup>Pathology and <sup>2</sup>Urology, Yonsei University College of Medicine, Seoul, Korea.

Solitary fibrous tumor (SFT) is a distinct spindle cell tumor arising mainly in the pleura, however, SFT of extra-pleural sites had been reported. To our knowledge, five cases of the urinary bladder SFT had been reported. We have recently experienced a case of SFT of the urinary bladder in a 56-year-old man who was admitted to the hospital with a 4-month history of voiding difficulty, frequency, and residual urine sensation. A computerized tomography scan revealed a 12cm sized intravesical mass. The mass was marginally excised under the impression of it being a benign spindle cell tumor by pre-operative needle biopsy. On gross examination, the mass was multinodular, creamy white, and the cut surface was fibrotic with a rubbery consistency. Microscopic examination revealed haphazardly arranged spindle cells with a lace-like deposition of inter- and pericellular collagen. Areas of increased cellularity show nuclear atypia and occasional mitoses (2-3/10HPF). The immunohistochemical staining revealed an intense CD34 and bcl-2 immunoreactivity. Although the exact biologic behavior of these tumors has not been clarified, most of the reported cases have undergone a benign clinical course.

**Key Words:** Solitary fibrous tumor, urinary bladder

## INTRODUCTION

Solitary fibrous tumor (SFT) was first described by Klemperer and Rabin in 1931 as a pleura-based lesion.<sup>1</sup> With the subsequent reports of Stout and Murray<sup>2</sup> it became known as localized or solitary fibrous tumor of the pleura and peritoneum, a term that served to distinguish it from the highly aggressive diffuse form of epithelial mesothelioma. Although this tumor is still best known as a pleural-based lesion, the SFT has been reported

in many extrapleural sites including liver, orbit, nasal passages, meninges, skin, respiratory tract, thyroid, and soft tissue.<sup>3-5</sup> SFT involving the urinary bladder is a very rare presentation and only seven cases have been reported in English literatures.<sup>6-9</sup> But it seems that the two cases of Bainbridge et al.<sup>6</sup> were included to the twelve cases of Mentzel et al.,<sup>9</sup> so really there have been only five cases reported. We report here on a SFT of the urinary bladder from a 56-year-old man.

## CASE REPORT

A 56-year-old man was admitted to the hospital with 4-month history of voiding difficulty. He complained of frequency, residual urine sensation, and interruption. The physical examination revealed a hard, non-tender low abdominal mass. An intravenous pyelography showed a huge filling defect in the bladder. Ultrasonography revealed a heterogeneous echogenic intravesical mass. Computerized tomography scans showed about a 12cm sized protruding intravesical mass without perivesical infiltration (Fig. 1). Transurethroscopey revealed a protruding mass at the dome of the bladder with intact mucosa. An ultrasonography-guided needle biopsy revealed a mesenchymal tumor, with the pathology report favoring a benign diagnosis. The tumor was located in the submucosa on the operation field, and a wide excision was performed. The patient has been doing well for 12 months after the operation.

## Pathologic findings

The mass was a 12 × 8 × 6cm, encapsulated

Received October 27, 2003  
Accepted January 26, 2004

Reprint address: requests to Dr. Nam Hoon Cho, Department of Pathology, Yonsei University College of Medicine, 134 Shinchon-dong, Seodaemun-gu, Seoul 120-752, Korea. Tel: 82-2-361-5242, Fax: 82-2-362-0860, E-mail: cho1988@yumc.yonsei.ac.kr

rubbery mass. Upon sectioning, dissection revealed a creamy white, multinodular, whorled fibrotic cut surface that very much resembled a leiomyoma of the uterus (Fig. 2). Microscopic examination revealed haphazardly arranged spindle cells with a lace-like deposition of inter- and pericellular collagen with multifocal hypercellular areas (Fig. 3A & 3B). These areas showed plump tumor cells with moderate cellular atypia and increased mitotic figures (2-3/ 10HPF). The immunohistochemical stain revealed CD34 and bcl-2 positive reactivity (Fig. 4A & 4B) and the results were negative for S-100 protein (Fig. 4C), smooth muscle actin (Fig. 4D), CD99 and desmin.

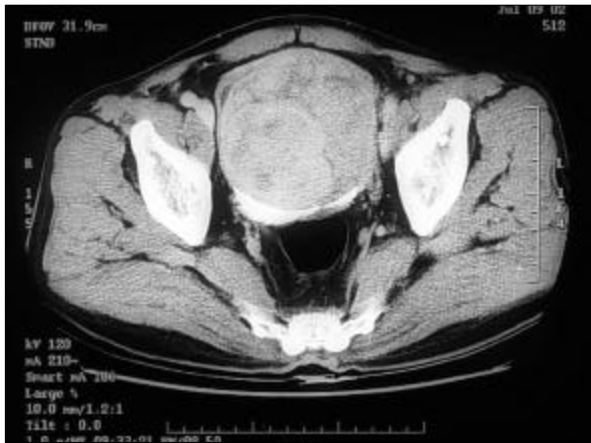

Fig. 1. CT scan revealed a 12 cm sized huge mass with heterogeneous attenuation in the urinary bladder.

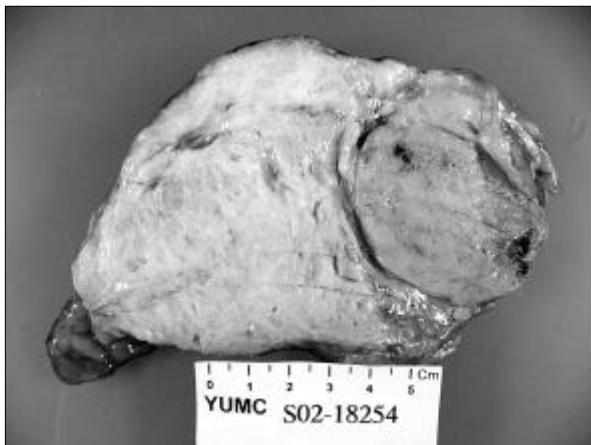

Fig. 2. The cut section showed a white ivory whorled rubbery surface with multifocal myxoid changes. A round nodule with an increased consistency is noted in the right side.

## DISCUSSION

It is now commonly accepted that solitary fibrous tumor (SFT) is derived from mesenchymal rather than mesothelial cells, and it shows a fibroblastic (and possibly myofibroblastic) differentiation.<sup>10</sup> Because of the variability of morphological patterns (patternless, storiform, fascicular, neural type, diffuse sclerosing and herringbone growth patterns) seen in SFT, this tumor may be misdiagnosed, especially if it occurs in an unusual location.<sup>9</sup> SFT can be diagnosed by means of its specific immunohistochemical markers;

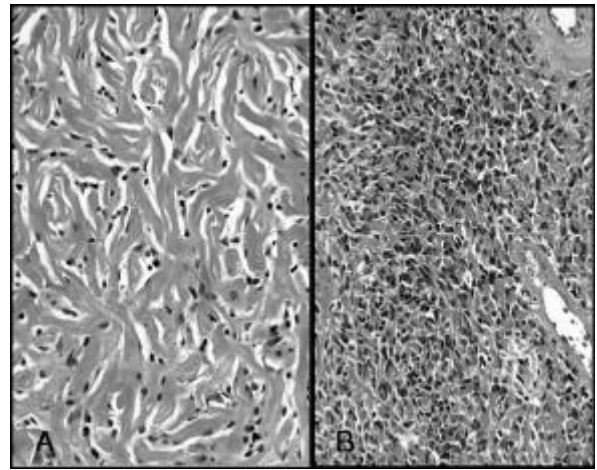


Fig. 3. A: The haphazardly arranged spindle cells with inter- and pericellular collagen deposition. (H-E, × 200). B: Focally, plump and epithelioid tumor cells with nuclear atypia were noted (H-E, × 200).

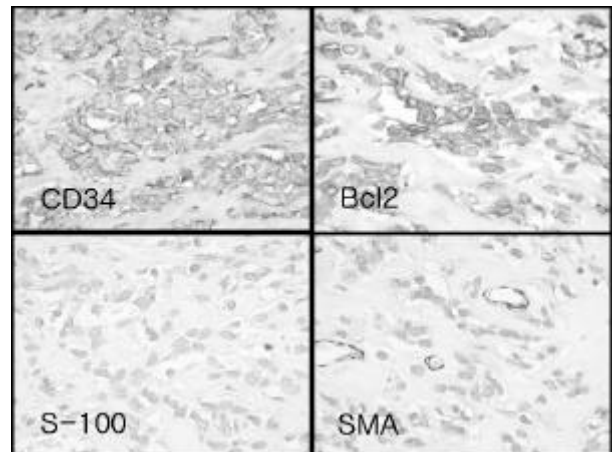


Fig. 4. The immunohistochemical staining revealed CD34, bcl-2 positive immunoreactivity and negative S-100, smooth muscle actin(SMA) immunoreactivity (× 400).

CD34 (90 - 95% of cases)<sup>11</sup> and CD99 (70% of cases).<sup>12</sup> In our case, CD34, which is a diagnostic marker for SFT, was diffusely and strongly expressed in the tumor cells, the same as is in other cases. But the CD99 marker showed a negative immunoreactivity. Suster et al.<sup>13</sup> reported that all 56 cases of their SFT findings at pleural and extrapleural sites were positive for bcl-2 protein, whereas only 38 (68%) were positive for CD34. Thus, it seems that bcl-2 is a more sensitive marker than CD34 in the diagnosis of SFT. Corti et al.<sup>8</sup> was the first to demonstrate bcl-2 immunoreactivity in SFT arising in the urinary bladder. In our case, bcl-2 positive immunoreactivity is also demonstrated. Solitary fibrous tumor (SFT) arising in the urinary bladder is very rare disease presentation and we have found just five cases in our review of literatures<sup>6-9</sup> (Table 1).

Because of the diverse morphologic features, the differential diagnosis for SFT of the urinary bladder includes several entities, such as sarcomatoid transitional cell carcinoma, leiomyosarcoma, inflammatory pseudotumor and hemangiopericytoma. The immunoreactivity of CD34 and bcl-2 facilitates the diagnosis of SFT in urinary bladder. Sarcomatoid transitional cell carcinoma was excluded by the lack of atypism, low mitotic activity and the failure of cytokeratin expression.<sup>6,8</sup> Leiomyosarcoma was excluded because it has a

more uniform storiform growth pattern, strongly eosinophilic cytoplasm, diffuse positivity for smooth muscle actin and a negativity for CD34 and bcl-2.<sup>13</sup> Spindle cell proliferations, such as inflammatory pseudotumor, pseudosarcomatous fibromyxoid tumor and post operative spindle cell nodules would also be diagnostic considerations.<sup>6</sup> These pseudosarcomatous spindle cell proliferations often have a more "reactive" appearance with mixed inflammatory cells, reactive small vessel proliferation, loose architecture and increased mitotic activity, and they do not show the strong CD34 immunoreactivity and sclerotic growth pattern usually seen in SFT.<sup>6</sup> Inflammatory pseudotumor is especially very difficult to distinguish preoperatively from SFT due to its similar radiological and echographic findings. SFT often shows a focal hemangiopericytomatous growth pattern and it can show neural-type palisading,<sup>10</sup> thereby potentially mimicking hemangiopericytoma (HPC) and nerve sheath neoplasia. The overall combination of growth patterns and negative S-100 protein immunoreactivity in SFT helps to exclude these considerations.<sup>6</sup> Because the HPC shows fairly consistent positivity for CD34, the immunoreactivity for CD34 can not distinguish SFT from HPC.<sup>14</sup> But the differentiation between SFT and HPC has become increasingly blurred. The delineation of HPC as a separate

**Table 1.** Clinical Data of the Reported Five Cases and Our Case of SFT Arising in Urinary Bladder

Case No.	Authors (reference)	Age /Sex	Presentation	Findings	Size (cm)	Treatment	Follow-up (months)
1	Kim SH et al. (this case)	56/M	Urinary frequency & residual urine sensation	Submucosal mass	12.0×8.0×6.0	Wide excision (completely excised)	NED(12)
2	Corti B et al. <sup>6</sup>	50/M	Pelvic pain, weight gain, & hypoglycemia	Submucosal nodular mass originating from the right lateral wall	6.5	Total cystectomy	NED(18)
3	Westra WH et al. <sup>5</sup>	67/M	Incidental cystoscopy finding during TURP	Submucosal polypoid mass in dome	4	Cystoprostatectomy (completely excised)	NED(9)
4	Westra WH et al. <sup>5</sup>	67/M	Incidental MRI finding (recurrent prostate cancer surveillance)	Submucosal polypoid nodule in dome	?	Transurethral resection (completely excised)	NED(1)
5	Bainbridge TC et al. <sup>4,9</sup>	50/F	Incidental US finding during right hemicolectomy	Solid mass, involving muscularis mucosa and submucosa	5.2×4.4×4.3	Transurethral resection	NED(18)
6	Bainbridge TC et al. <sup>4,9</sup>	42/M	Pelvic "pressure"	A huge mural mass	17.0×13.5×15.5	Wide excision	NED(3)

entity may have become obsolete since its histopathological features, as are generally understood at the present time, are also shared by a variety of other soft tissue tumors.<sup>14</sup>

Although most cases are benign, the behavior of SFT is still very unpredictable. Roughly,<sup>10</sup> to 15% of SFT can behave aggressively, and so thus long-term follow-up is mandatory.<sup>15-17</sup> There is no strict correlation between histological feature and clinical behavior.<sup>10</sup> The histological criteria of malignant SFT are increased cellularity, moderate to marked cytological atypia, necrosis, increased mitoses (>4 mitoses/10HPF) and/or an infiltrative margin.<sup>10</sup> Although the presence of moderate cytological atypia and increased mitoses (2-3/10 HPF) were not present in the previously reported five cases, in our case, these features were not sufficiently displayed for the tumor to be diagnosed as a malignant SFT, according to these criteria.<sup>10</sup> Thus we were obligated to diagnose this case as a SFT with uncertain biologic behavior. We recommended a close follow-up to the clinician. The patient has been well, although the follow up period (12 months) has been rather short. All the previous reported cases occurred in middle age and there has no evidence of recurrent disease irrespective of the type of operation (Table 1). In conclusion, SFT of the urinary bladder seems to have an indolent biologic behavior that is independent of their size. A complete excision seems to be a sufficient treatment of SFT in the urinary bladder.

## REFERENCES

- Klemperer P, Rabin CB. Primary neoplasm of the pleura: a report of five cases. *Arch Pathol* 1931;11:385-412.
- Stout AP, Murray MR. Hemangiopericytoma: a vascular tumor featuring Zimmermann's pericytes. *Ann Surg* 1942;116:26-33.
- Weiss SW, Goldblum JR. Perivascular tumors. In: Weiss SW, Goldblum JR, eds. *Soft tissue tumors*. 4th ed. St. Louis, Missouri: Mosby; 2001. p.1021-31.
- Lee MK, Shin DH, Cho MS, Kim YM, Kim J. Extrapleural solitary fibrous tumor. - A clinical & pathological study of 8 cases- *Korean J Pathol* 1999;33:108-14.
- Kim BK, Kang DW, Kim KH, Min SK, Kim JM, Song KS, et al. Solitary fibrous tumor. - A clinicopathologic review of five cases- *Korean J Pathol* 1999;33:115-20.
- Bainbridge TC, Singh RR, Mentzel T, Katenkamp D. Solitary fibrous tumor of urinary bladder. Report of two cases. *Hum Pathol* 1997;28:1204-6.
- Westra WH, Grenko RT, Epstein J. Solitary fibrous tumor of the lower urogenital tract: A report of five cases involving the seminal vesicles, urinary bladder, and prostate. *Hum Pathol* 2000;31:63-8.
- Corti B, Carella R, Gabusi E, D'Errico A, Martorana G, Grigioni WF. Solitary fibrous tumour of the urinary bladder with expression of bcl-2, CD34, and insulin-like growth factor type II. *Eur Urol* 2001;39:484-8.
- Mentzel T, Bainbridge TC, Katenkamp D. Solitary fibrous tumour: clinicopathological, immunohistochemical, and ultrastructural analysis of 12 cases arising in soft tissues, nasal cavity and nasopharynx, urinary bladder and prostate. *Virchow Arch* 1997;430:445-53.
- Moran CA, Suster S, Koss MN. The spectrum of histologic growth patterns in benign and malignant fibrous tumors of the pleura. *Semin Diag Pathol* 1996;9:169-80.
- Van de Rijn M, Lombard CM, Rouse RV. Expression of CD34 by solitary fibrous tumors of the pleura, mediastinum, and lung. *Am J Surg Pathol* 1994;18:814-20.
- Renshaw AA. O13(CD99) in spindle cell tumors. Reactivity with hemangiopericytoma, solitary fibrous tumor, synovial sarcoma, and meningioma but rarely with sarcomatoid mesothelioma. *Appl Immunohistochem* 1995;3:250-6.
- Suster S, Fisher C, Moran CA. Expression of bcl-2 oncoprotein in benign and malignant spindle cell tumors of soft tissue, skin, serosal surfaces, and gastrointestinal tract. *Am J Surg Pathol* 1998;22:863-72.
- Guilou L, Flechter JA, Flechter CDM, Mandahl N. Extrapleural solitary fibrous tumour and hemangiopericytoma. In: Fletcher CDM, Unni KK, Mertens F, editors. *Pathology & Genetics. Tumours of Soft Tissue and Bone*. 1st ed. Lyon, France: WHO IARC Press; 2002. p.86-93.
- Fukunaga M, Naganuma H, Nikaito T, Harada T, Ushigome S. Extrapleural solitary fibrous tumor: a report of seven cases. *Mod Pathol* 1997;10:443-50.
- Hasegawa T, Matsuno Y, Shimoda T, Hasegawa F, Sano T, Hirohashi S. Extrathoracic solitary fibrous tumors: their histological variability and potentially aggressive behavior. *Hum Pathol* 1999;30:1464-73.
- Vallat-Decouvelaere AV, Dry SM, Fletcher CD. Atypical and malignant solitary fibrous tumors in extrathoracic locations: evidence of their comparability to intrathoracic tumors. *Am J Surg Pathol* 1998;22:1501-11.