

가

A Comparative Study of Donor Site Morbidity between Patients with or without Iliac Donor Site Reconstruction after Anterior Thoracolumbar Spinal Fusion using Auto-Iliac Tricortical Strut done Graft.

Hyung Chan Kim, M.D., Seong Hwan Moon, M.D., Dong Sik Sim, M.D., and Hwan Mo Lee, M.D.

Department of Orthopaedic Surgery, Yonsei University College of Medicine, Seoul, Korea

– Abstract –

Study Design: A comparative retrospective study between those who have and have not undergone donor site reconstruction after thoracolumbar spinal anterior interbody fusion using an auto-iliac bone graft.

Objectives: To determine the efficacy of iliac reconstruction in reducing iliac donor site morbidity.

Summary of Literature Review: An autogenous bone graft harvested from the iliac crest is still the gold standard for spinal anterior interbody fusion. However, defects of a significant size often remain in the donor site, which may cause pain, pelvic instability and cosmetic deformity etc. Iliac donor site reconstruction with bone cement is one of the methods for reducing the donor site morbidity, with a relatively easy technique.

Materials and Methods: A review of patients who underwent iliac bone graft harvesting, with or without reconstruction, by a single orthopaedic surgeon was conducted. The iliac donor site morbidity, at least one after remote surgery was compared in those who had and had not undergone iliac reconstruction. All patients were evaluated by an independent observer. During a two and half year period, 61 patients met the inclusion criteria. Twenty-three patients underwent iliac donor site reconstruction with bone cement and 9 with auto rib bone reconstruction, while the remaining 29 had no donor site reconstruction. Patients were asked to assess the duration and severity of their donor site pain, using a visual analogue scale (VAS), and other morbidity, such as cosmetic deformity.

Results: The severity of chronic donor site pain was significantly reduced in the donor site reconstruction group; however, there were no statistically significant differences, other than chronic pain, in the morbidities.

Conclusions: Iliac donor site reconstruction, with bone cement or auto-rib bone, is a relatively easy technique to perform after anterior spinal fusion. Better results can be expected, especially in reducing postoperative donor site pain.

Key words: anterior thoracolumbar spinal fusion, donor site morbidity, bone cement, iliac reconstruction

Address reprints request to

Hwan Mo Lee, M.D.

Department of Orthopaedic Surgery, Yonsei University College of Medicine

#134 Shinchon-dong, Seodaemun-gu, Seoul, 120-752, Korea

Tel: 82-2-361-5648, Fax: 82-2-363-1139, E-mail: hwanlee@yumc.yonsei.ac.kr

29

가

가(22)

(15) (6), (4

가 가 (9), (4

1,2) 가 가 Kummell (1)

가

2.

2.8% 49% 3-6)

cm Reciprocating saw

가 2 cm

7,8)

6,9)

3. 가 (Table 1)

가 1 . VAS (Visual Analogue Scale)

가 ,

3 가

1. 가

1999 1 2001 6 가 SAS V 8.1

가 Exact test t- Fisher's 0.05

가 가 61 45

, 9 가 23

Table 1. Questionnaire

1.						?
2.						?
3.						?
4.						?
5.						?
6.						?
7.	1	10				
(1			10	가).
0						10
8.		가			?	
9.	가				?	
10.						가
						?

Table 2. Duration of donor site pain

	Iliac reconstruction*	Non-reconstruction†
Less than 6 months (PO)	13	9
6~12 months	5	6
More than 12 months	3	9
Total‡	21	24

*Iliac reconstruction: Patients who received iliac reconstruction with cement or auto rib bone.

†Non-reconstruction: Patients who did not received iliac reconstruction.

PO: Post operation

‡Total: Patients who did not experience donor site pain were excluded.

1.									2.
		9	62	15	1)				?
60			가 2			32	21		
				가		29	24		
		4	3						
1		2							
				1	2)				?
						21	13		
	3						8	6	
				1					
									24 (

1) 9 6 15 (Table 3).
 6
 (Table 2). 6 ?
 6
 3) ? 11
 12
 3 9 가
 1
 (p<0.05) 7) 0 10
 (0 10 가
 4)).
 ? Visual Analogue Scale
 1 2.9 ,
 4.4
 (L3/4-L5/S1) 50 (p<0.05).
 41 (82%) 가
 4 가 8) 가 ?
 5 32 6
 5) ?
 1 16 29 15
 가

Table 3. Frequency of donor site pain

	Iliac reconstruction	Non-reconstruction
Rare	1	1
Seldom	10	4
Occasional	6	13
Frequent	3	4
Continuous	1	2
Total [‡]	21	24

[‡]Total: Patients who did not experience donor site pain were excluded.

Table 4. Distribution of donor site morbidity

	Iliac reconstruction	Non-reconstruction
Pain	7	13
Cosmetic reason	1	3
Weakness	0	2
No morbidity	24	11
Total	32	29

(p < 0.05).

9) 가 ? 가 3. 가

VAS score 3 2, 3, 3 1 6 9 가

3 1 2 (21) 가 (9)

10) 가 ? 1 1

(Table 4) , 7 52 1 4

1 (Fig. 1A) 가 (Fig. 1B)

13 2 가 3 , 1 (Fig. 1C).

가 2 2: 49 1 5

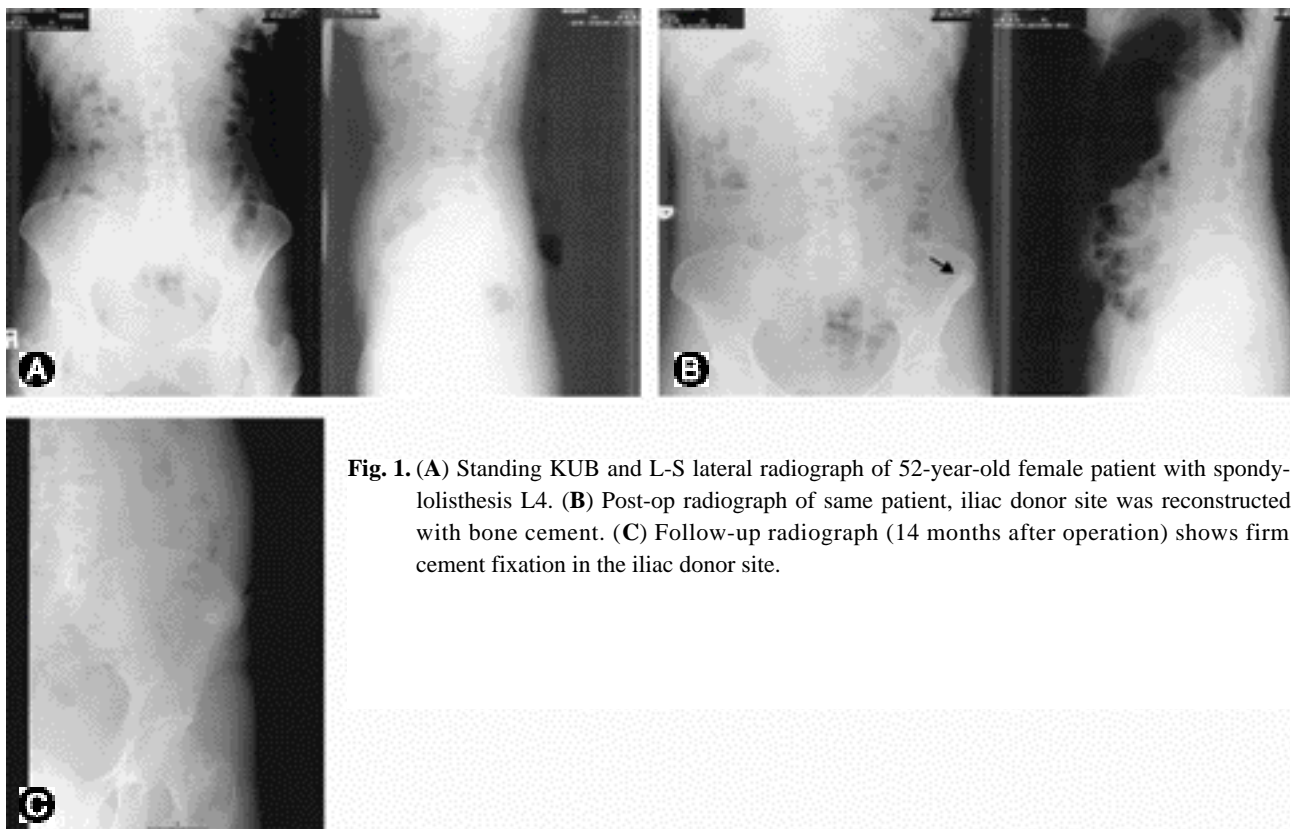


Fig. 1. (A) Standing KUB and L-S lateral radiograph of 52-year-old female patient with spondylolisthesis L4. (B) Post-op radiograph of same patient, iliac donor site was reconstructed with bone cement. (C) Follow-up radiograph (14 months after operation) shows firm cement fixation in the iliac donor site.

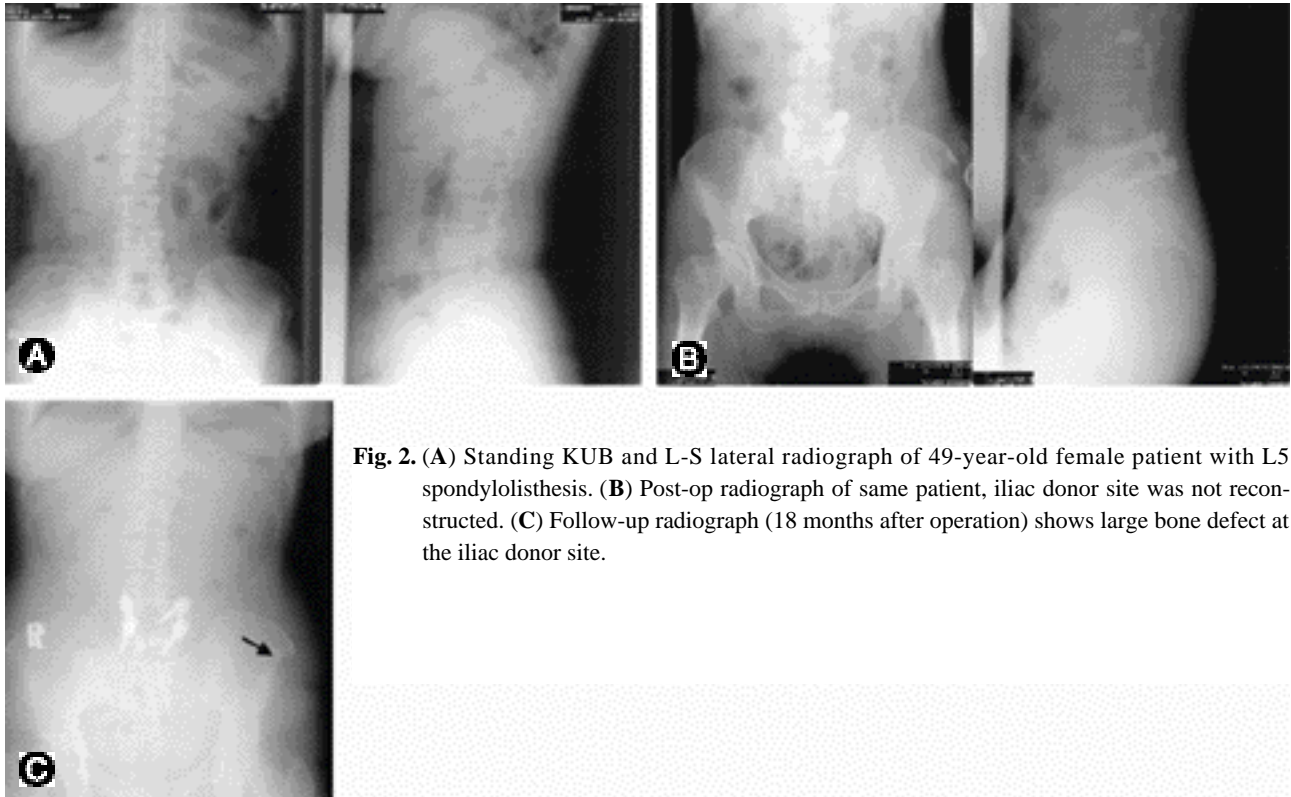


Fig. 2. (A) Standing KUB and L-S lateral radiograph of 49-year-old female patient with L5 spondylolisthesis. (B) Post-op radiograph of same patient, iliac donor site was not reconstructed. (C) Follow-up radiograph (18 months after operation) shows large bone defect at the iliac donor site.

(Fig. 2A) 가 3
 (Fig. 2B) 18 6 9,11-13)
 (Fig. 2C). 가 가
 가 가 45 가
 가 6 11 23 1
 Arrington¹⁰⁾, 19.7%
 (minor complication),
 (major complication) 61
 6.4% (minor complication) 3
 가 가 가 Lubicky DeWald⁷⁾ 가 14-16)
 1 가 Harris⁸⁾

가
Yang ¹⁷⁾ Poly-lactic acid
가
Eisenstein⁶⁾
가
가
가
1
가
29
6
6
1
12
가 3
가 9
VAS
VAS

가
가
가
가
가
61
32
VAS
가
가

REFERENCES

- 1) **Hollowell JP, Vollmor DG, Wilson CR, Pintor FA, Yoganandon N:** *Biomechanical analysis of thoracolumbar interbody constructs.* *Spine* 1996;21:1032-1036.
- 2) **Goulet JA, Senunas LE, DeSilva GL, Greenfield ML:** *Autogenous iliac bone graft: Complications and functional assessment.* *Clin Orthop* 1997;339:76-81.
- 3) **Banwart JC, Asher MA, Hassanein RS:** *Iliac crest bone graft harvest donor site morbidity.* *Spine* 1995;20:1055-1060.
- 4) **Sawin PD, Traynelis VC, Menezes AH:** *A comparative analysis of fusion rates and donor site morbidity for autogenous rib and iliac crest bone grafts in posterior cervical fusion.* *J Neurosurg* 1998;88:255-265.
- 5) **Schnee CL, Freese A, Weil RJ, Marcotte PJ:** *Analysis of harvest morbidity and radiographic outcome using auto-*

- graft for anterior cervical fusion. *Spine* 1997;22:2222-2227.
- 6) **Summers BN, Eisenstein SM:** Donor site pain from the ilium. A complication of lumbar spine fusion. *J Bone Joint Surg* 1989;71-B:677-680.
 - 7) **Lubicky JP, DeWald RL:** Methylmethacrylate reconstruction of large iliac crest bone graft donor sites. *Clin Orthop* 1982;164:252-256.
 - 8) **Harris MB, Davis J, Gertzbein SD:** Iliac crest reconstruction after tricortical graft harvesting. *J Spinal Disord* 1994;7:216-221.
 - 9) **Wang JM, Kim DJ:** Clinical course of iliac bone graft donor site morbidity. *J Kor Spine Surg* 1996;3:154-160.
 - 10) **Arrington ED, Smith WJ, Chambers HG, Bucknell AL, Davino NA:** Complications of iliac crest bone graft harvesting. *Clin Orthop* 1996;329:300-309.
 - 11) **Fernyhough JC, Schimandle JJ, Weigel MC, Edwards CC, Levine AM:** Chronic donor site pain complicating bone graft harvesting from the posterior iliac crest for spinal fusion. *Spine* 1992;17:1474-1480.
 - 12) **Robertson PA, Wray AC:** Natural history of posterior iliac crest bone graft donation for spinal surgery. A prospective analysis of morbidity. *Spine* 2001;26:1473-1476.
 - 13) **Heary RF, Schlenk RP, Sacchieri TA, Barone D, Brotea C:** Persistent iliac donor site pain: Independent outcome assessment. *Neurosurgery* 2002;50:510-517.
 - 14) **Linovitz RJ, Peppers TA:** Use of advanced formulation of β -tricalcium phosphate as a bone extender in interbody lumbar fusion. *Orthopedics* 2002;25:585-589.
 - 15) **Boden SD:** Overview of the biology of lumbar spine fusion and principle for selecting a bone graft substitute. *Spine* 2002;27:26-31.
 - 16) **Thalgott JS, Klezl Z, Timlin M, Giuffre JM:** Anterior lumbar interbody fusion with processed sea coral (coralline hydroxyapatite) as part of a circumferential fusion. *Spine* 2002;27:518-527.
 - 17) **Yang MY, Levi AD, Shah S, Green BA:** Polylactic acid mesh reconstruction of the anterior iliac crest after bone harvesting reduces early postoperative pain after anterior cervical fusion surgery. *Neurosurgery* 2002;51:413-416.
 - 18) **Epstein NE, Hollingsworth R:** Does donor site reconstruction following anterior cervical surgery diminish postoperative pain? *J Spinal Disord* 2003;16:20-26.



: 가

가

: 가

: 1999 1 2001 6

가

가 가 61

45

23

9 가

, 29

1

VAS(Visual Analogue Scale)

가

(,)

SAS V 8.1

: (6)

가 (1)

(p<0.05) VAS

(p<0.05).

: 가

가

: , 가 , , ,