

급성 우심실 심근경색증에서 동반된 저산소증의 원인으로 난원공 개존을 통한 우좌단락

연세대학교 의과대학 심장혈관병원 심장내과학교실, 심혈관연구소

Right-to-Left Shunting through a Patent Foramen Ovale as a Cause of Hypoxemia in a Patient with Acute Right Ventricular Infarction Diagnosed by Contrast Echocardiography

Chi Young Shim, MD, Jong-Won Ha, MD, PhD, Seung-Hoon Choi, MD, Jin-Bae Kim, MD, Won-Ho Kim, MD, Jong-Youn Kim, MD, Seokmin Kang, MD, PhD, Se-Joong Rim, MD, PhD and Namsik Chung, MD, PhD

Cardiology Divisions, Yonsei Cardiovascular Hospital and Cardiovascular Research Institute, Yonsei University College of Medicine, Seoul, Korea

Right ventricular (RV) infarction is a well-recognized complication of acute inferior myocardial infarction. Right-to-Left shunt through a patent foramen ovale (PFO) is an unusual complication of acute RV myocardial infarction that can result in the development of severe hypoxemia. However, the diagnosis may not be easy without high index of suspicion and echocardiography combined with an echocardiographic contrast (agitated saline) is useful diagnostic imaging modality in this regard. We report a case of acute inferior myocardial infarction and RV infarction associated with unexplained hypoxemia. Contrast echocardiography detected a significant right to left shunt through patent foramen ovale, which considered as a cause of hypoxemia in this patient.

KEY WORDS : Patent foramen ovale · Right ventricular infarction · Contrast echocardiography.

서 론

가

1-3) 2)4-7) 4-7)

8) 9)

증 례

: 2004 7 1 52 2

: 2004 7 15

: , 120 - 752 134 가

: (02) 361 - 7049 · : (02) 393 - 2041 30

E - mail : jwha@yumc.yonsei.ac.kr

85/65 mmHg, 53
 / .
 , aVF 3~4 mm ST
 V3~6 ST
 (Fig. 1A, B).

24,520/mm³(71.9%),
 15.9 g/dL, 45.6%, 277,000/
 mm³ . Na⁺ 139.1 mmol/L,
 K⁺ 3.8 mmol/L, Cl⁻ 105.6 mmol/L, CO₂ 18.5 mmol/L
 BUN/Cr 27.8/1.2 mg/dL,
 GOT/GPT 206/164 IU/L ,
 CK - MB 139.4 ng/mL, Troponin - T 3.60 ng/mL

ST

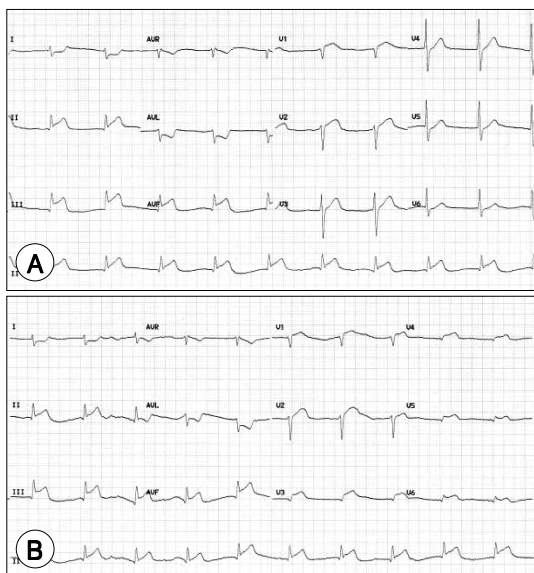


Fig. 1. A : Twelve lead electrocardiogram showing acute inferior myocardial infarction. **B :** Right precordial lead electrocardiogram showing right ventricular infarction.

1 ST 7 mm
 55/25
 mmHg
 80%
 (Fig. 2)
 100%
 60~65 mmHg,
 가 90~94%
 40%

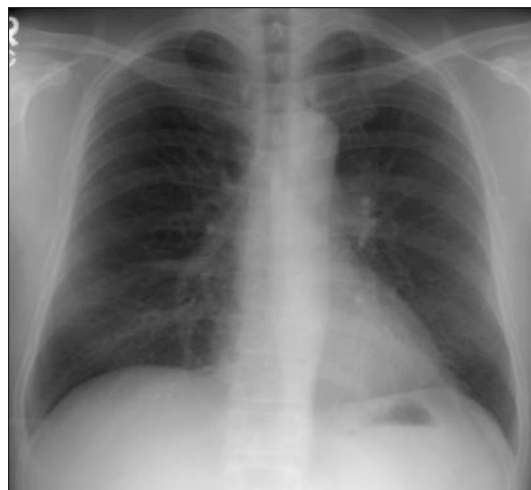

Fig. 2. Chest X-ray film at the time of hypoxemia.

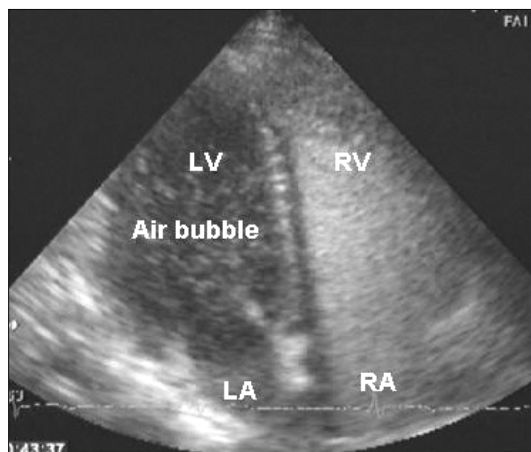


Fig. 3. Saline contrast echocardiogram show right-to-left shunt through patent foramen ovale. The air bubbles were showed at the left atrium and ventricle.

40.3 mmHg

Morris AL 1978 10)

가

가

1970

(Fig. 3).

가 가 18-21)

고 찰

가

가

hand - agitated saline

22)

가

가

가

25%

가

11)

가

가

12-14)

중심 단어 :

가 15)

REFERENCES

- 1) Isner JM, Roberts WC. *Right ventricular infarction complicating left ventricular infarction secondary to coronary heart disease. Am J Cardiol 1978;42:885-94.*
- 2) Rigo P, Murray M, Taylor DR, et al. *Right ventricular dysfunction detected by gated scintiphography in patients with acute inferior myocardial infarction. Circulation 1975;52:*

16)17)

- 268-74.
- 3) Wackers FJ, Lie KI, Sokole EB, Res J, Van der Schoot JB, Durrer D. *Prevalence of right ventricular involvement in inferior wall infarction assessed with myocardial imaging with thallium-201 and technetium-99m pyrophosphate. Am J Cardiol 1978;42:358-62.*
 - 4) Cohn JN, Guiha NH, Broden MI, Limas CJ. *Right ventricular infarction: Clinical and hemodynamic features. Am J Cardiol 1974;33:209-14.*
 - 5) Lopez-Sendon J, Coma-Camella I, Gamallo C. *Sensitivity and specificity of hemodynamic criteria in the diagnosis of acute right ventricular infarction. Circulation 1981;64:515-25.*
 - 6) Lloyd EA, Gersh BJ, Kennelly BM. *Hemodynamic spectrum of "dominant" right ventricular infarction in 19 patients. Am J Cardiol 1981;48:1016-22.*
 - 7) Lorell B, Leinbach RC, Pohost GM, et al. *Right ventricular infarction. Clinical diagnosis and differentiation from cardiac tamponade and pericardial constriction. Am J Cardiol 1979;43:465-71.*
 - 8) Zone DD, Botti RE. *Right ventricular infarction with tricuspid insufficiency and chronic right heart failure. Am J Cardiol 1976;37:445-8.*
 - 9) Sclarovsky S, Zafri N, Strasberg B, et al. *Ventricular fibrillation complicating temporary ventricular pacing in acute myocardial infarction: significance of right ventricular infarction. Am J Cardiol 1981;48:1160-6.*
 - 10) Morris AL, Donen N. *Hypoxia and intracardiac right-to-left shunt Complicating inferior myocardial infarction with right ventricular extension. Arch Intern Med 1978;138:1405-6.*
 - 11) Kerut EK, Norfleet WT, Plotnick GD, Giles TD. *Patent foramen ovale: a review of associated conditions and the impact of physiological size. J Am Coll Cardiol 2001;38:613-23.*
 - 12) Ciafone RA, Aroesty JM, Weintraub RM, LaRaia PJ, Paulin S. *Cyanosis in uncomplicated atrial septal defect with normal cardiac and pulmonary arterial pressures. Chest 1978;74:596-9.*
 - 13) Thomas JD, Tabakin BS, Ittleman FP. *Atrial septal defect with right to left shunt despite normal pulmonary artery pressure. J Am Coll Cardiol 1987;9:221-4.*
 - 14) Godart F, Rey C, Prat A, et al. *Atrial right-to-left shunting causing severe hypoxaemia despite normal right-sided pressures: report of 11 consecutive cases corrected by percutaneous closure. Eur Heart J 2000;21:483-9.*
 - 15) Shnaider H, Shiran A, Lorber A. *Right ventricular diastolic dysfunction and patent foramen ovale causing profound cyanosis. Heart 2004;90:e31.*
 - 16) Silver MT, Lieberman EH, Thibault GE. *Refractory hypoxemia in inferior myocardial infarction from right-to-left shunting through a patent foramen ovale: a case report and review of the literature. Clin Cardiol 1994;17:627-30.*
 - 17) Amsel BJ, Rodrigus I, De Paep R, De Raedt H, Moulijn AC. *Right-to-left flow through a patent foramen ovale in acute right ventricular infarction: two case reports and a proposal for management. Chest 1995;108:1468-71.*
 - 18) Seward JB, Tajik AJ, Hagler DJ, Ritter DG. *Peripheral venous contrast echocardiography. Am J Cardiol 1977;39:202-12.*
 - 19) Dubourg A, Bourdarias JP, Farcot JC, Gueret P, Terdjman M, Ferrier A, Rigaud M, Bardet JC. *Contrast echocardiographic visualization of cough-induced right to left shunt through a patent foramen ovale. J Am Coll Cardiol 1984;4:587-94.*
 - 20) Shub C, Dimopoulos DN, Seward JB, Callahan JR, Tancredi RG, Schattenberg TT, Reeder GS, Hagler DJ, Tajik AJ. *Sensitivity of two-dimensional echocardiography in the direct visualization of atrial septal defect utilizing the subcostal experience with 154 patients. J Am Coll Cardiol 1983;2:127-35.*
 - 21) Ha JW, Shin MS, Kang S, Pyun WB, Jang GJ, Byun KH, Rim SJ, Huh J, BI Lee, N Chung. *Enhanced detection of right-to-left shunt through patent foramen ovale by trans-thoracic contrast echocardiography using harmonic imaging. Am J Cardiol 2001;87:669-71.*
 - 22) Fessler MB, Lepore JJ, Thompson BT, Semigran MJ. *Right to left shunting through a patent foramen ovale in right ventricular infarction: Improvement of hypoxemia and hemodynamics with inhaled nitric oxide. J Clin Anesth 2003;15:371-4.*