

Clinical Article

Long Term Efficacy of Posterior Lumbar Interbody Fusion with Standard Cages alone in Lumbar Disc Diseases Combined with Modic Changes

Young-Min Kwon, M.D., Dong-Kyu Chin, M.D., Ph.D., Byung-Ho Jin, M.D., Ph.D., Keun-Su Kim, M.D., Ph.D., Yong-Eun Cho, M.D., Ph.D., Sung-Uk Kuh, M.D., Ph.D.

Department of Neurosurgery, Spine and Spinal Cord Institute, Gangnam Severance Spine Hospital, Yonsei University College of Medicine, Seoul, Korea

Objective : Posterior lumbar interbody fusion (PLIF) is considered to have the best theoretical potential in promoting bony fusion of unstable vertebral segments by way of a load sharing effect of the anterior column. This study was undertaken to investigate the efficacy of PLIF with cages in chronic degenerative disc disease with Modic degeneration (changes of vertebral end plate).

Methods : A total of 597 patients underwent a PLIF with threaded fusion cages (TFC) from 1993 to 2000. Three-hundred-fifty-one patients, who could be followed for more than 3 years, were enrolled in this study. Patients were grouped into 4 categories according to Modic classification (no degeneration : 259, type 1 : 26, type 2 : 55, type 3 : 11). Clinical and radiographic data were evaluated retrospectively.

Results : The clinical success rate according to the Prolo's functional and economic outcome scale was 86% in patients without degeneration and 83% in patients with Modic degeneration. The clinical outcomes in each group were 88% in type 1, 84% in type 2, and 73% in type 3. The bony fusion rate was 97% in patients without degeneration and 83% in patients with Modic degeneration. The bony fusion rate in each group was 81% in type 1, 84% in type 2, and 55% in type 3. The clinical success and fusion rates were significantly lower in patients with type 3 degeneration.

Conclusion : The PLIF with TFC has been found to be an effective procedure for lumbar spine fusion. But, the clinical outcome and bony fusion rates were significantly low in the patients with Modic type 3. The authors suggest that PLIF combined with pedicle screw fixation would be the better for them.

KEY WORDS : Modic degeneration · Degenerative disc disease · Posterior lumbar interbody fusion · TFC.

INTRODUCTION

Chronic low back pain has been one of the most common causes of disability in adults and is consequently one of the most common reasons for early retirement in industrialized societies. Magnetic resonance imaging (MRI) findings of chronic low back pain have shown not only a wide spectrum of disc abnormalities, including degenerative black disc, disc bulging, disc protrusion, and annular tears, as evidenced by high-signal-intensity zones, but also vertebral

end-plate changes^{1,3,4,11,20,23}. Weishaupt et al.²⁴ reported that abnormalities of the endplate and adjacent bone marrow described by Modic et al.^{15,16} were uncommon in asymptomatic volunteers aged 20-50 years. They concluded that endplate abnormalities appear to be useful in the prediction of painful disc derangement in patients with symptomatic low back pain. Braithwaite et al.⁵ suggested that vertebral end-plate has been identified as a possible source of discogenic low back pain. Therefore, Modic changes appear to be a relatively specific but insensitive sign of a painful lumbar disc in patients with discogenic low back pain.

Buttermann et al.⁷ suggested that abnormal endplates associated with inflammation are a source of pain, and treating endplates directly with anterior fusion may be a preferred treatment for this subset of degenerative patients. Chataigner et al.⁸ suggested that anterior fusion is effective for the treatment of low-back pain due to degenerative disc

• Received : June 26, 2009 • Revised : September 4, 2009
• Accepted : October 4, 2009
• Address for reprints : Dong Kyu Chin, M.D., Ph.D.
Department of Neurosurgery, Spine and Spinal Cord Institute,
Gangnam Severance Spine Hospital, Yonsei University College of
Medicine, 712 Eonju-ro, Gangnam-gu, Seoul 135-720, Korea
Tel : +82-2-2019-3390, Fax : +82-2-3461-9229
E-mail : dkchin@yuhs.ac

disease, when associated with vertebral plate changes.

Spinal fusion was introduced as a treatment option for chronic low back pain more than 70 years ago. Fritzell et al.⁹⁾ reported that lumbar fusion in patients with severe chronic low back pain can diminish pain and decrease disability more efficiently than commonly used nonsurgical treatment through a prospective multicenter randomized controlled trial from the Swedish Lumbar Spine Study Group. Different surgical techniques are available. In the literatures mentioned above, anterior lumbar interbody fusion or posterolateral fusion was performed in patients with chronic degenerative disc associated with vertebral end plate changes.

Posterior lumbar interbody fusion (PLIF) procedures have distinct mechanical advantages over lateral or posterolateral procedures, which include a wider fusion area, anterior column support, familiar surgical anatomy, restoration of collapsed disc height, and indirect decompression of nerve^{2,10,13,14,17,21)}. Autologous cancellous bone is the preferred graft material, but it is too soft to maintain space during fusion without mechanical support. Various methods have been used in the past to maintain the graft integrity during fusion development.

The purpose of the current study was to assess the long-term efficacy of PLIF with a threaded fusion cage (TFC) according to vertebral end-plate changes in degenerative disc disease.

MATERIALS AND METHODS

Materials

Five-hundred-and-ninety-seven patients underwent a PLIF procedure in which cages were used in our institution from January 1993 to December 2000. Among them, 351 patients with more than three years of follow-up were enrolled in this study. All patients underwent magnetic resonance imaging (MRI) scanning preoperatively and were classified into 4 groups according to vertebral end-plate changes as follows : No vertebral end plate change, Modic type 1, Modic type 2, Modic type 3. There was evidence of associated degenerative disc disease at every level of involvement in all cases. Two-hundred-fifty-nine patients are enrolled in patients with no vertebral end plate degeneration, 26 patients were with Modic type 1, 55 patients were with Modic type 2 and 11 patients were with Modic type

3. PILF was performed through a conventional posterior approach using cage. A TFC filled with laminar bone chips was implanted. The clinical and radiographic data were evaluated retrospectively. A total of 497 levels were implanted with TFC in 351 patients. The mean [\pm standard deviation (SD)] of patient's age was 47.4 ± 11.4 years and the mean (\pm SD) follow-up period was 59.8 ± 9.1 months. The male to female ratio was 1 : 1.95 (= 119 : 232) (Table 1).

Methods

Postoperative improvement of low back pain was assessed using visual analog scale (VAS) and Prolo's scale¹⁸⁾, which was further analyzed according to preoperative bone marrow degeneration. Prolo's score of 9 to 10 was classified as an excellent, 7 to 8 as a good, 5 to 6 as a fair and below 4 was as a poor clinical outcome group. For radiologic evaluation, simple X-rays obtained before the procedure and 3 years or later postoperatively were compared. In all patients, plain anteroposterior and lateral X-rays of lumbar spines were obtained before the operation for baseline evaluation. Further, simple lateral X-rays of lumbar spines were taken while patients were seated with full flexion of the vertebral columns and standing at full extension for a dynamic study of segmental instability of lumbar spines.

Bony fusion was evaluated based according to the Ray criteria¹⁹⁾, details of which were as follows : 1) absence of motion of lumbar segments by the analysis of angular instability, 2) absence of any dark halo around a cage on simple radiographic view of lumbar spines, and 3) continuous presence of visible bone within each cage, as seen on the plain anteroposterior X-ray views. Since metallic cages, such as TFC, have a difficulty to determine the bony bridge inside the cage, we added 2 more criteria for evaluation of bony fusion as follows : 4) Posterior bony bridging, and 5) no traction spur formation.

From the criteria mentioned above, we concluded that

Table 1. Demographics of patients

Characteristic	No end plate degeneration	Modic type 1	Modic type 2	Modic type 3	Total
No. of patients	259	26	55	11	351
Levels of fusion (segments)	353	39	86	19	497
Sex					
Male	97	10	11	1	119
Female	162	16	44	10	232
Age (years)					
Mean	46.9	48.4	48.5	52.4	47.4
Range	23-74	23-66	27-72	37-68	23-74
Mean follow up period (months)					
Mean	61.5	53.5	56.3	51	59.8
Range	36-72	36-71	36-71	36-67	36-72

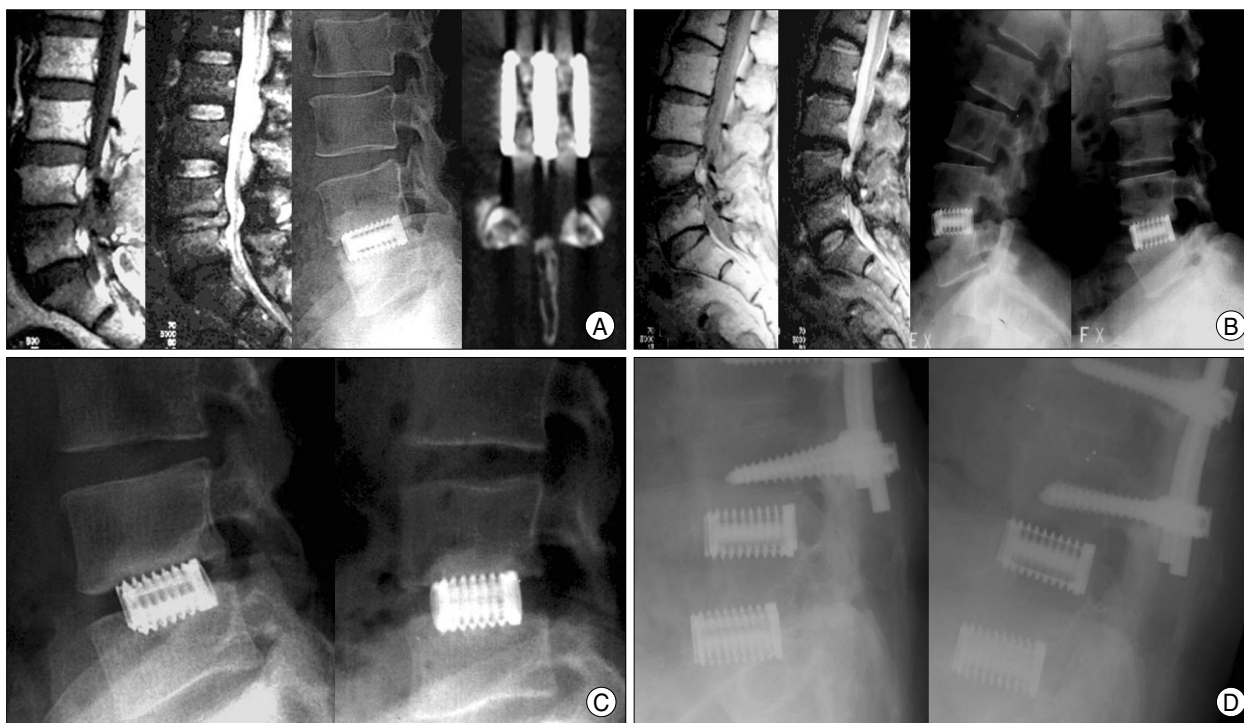


Fig. 1. A : Patient with chronic degenerative disc disease with stenosis at L4/5 who underwent posterior lumbar interbody fusion with threaded fusion cages. Magnetic resonance imaging (MRI) also reveals Modic type 1 degeneration at vertebral end plate. Plain X-ray and lumbar CT scan after post-operative 47 months show a posterior bony bridge without traction formation and halo around the cage. This patient is compatible with bony fusion criteria. B : Patient who shows Modic type 3 degeneration at vertebral end plate on MRI. Post-operative 26 months plain film shows instability at flexion/extension view. C : Patient with sclerosis at upper end vertebral plate shows settling of cages and incomplete formation of bony bridge at plain lateral film. D : Post-operative 60 months plain film shows instability and halo around cages at flexion/extension view. These patients are classified as a non-union by bony fusion criteria.

fusion status is nonunion if any one of five were not shown (Fig. 1).

Statistical analysis

For each measurement, the mean and standard deviation were calculated. ANOVA was used for the comparison between the 3 groups. Statistical significance level was set at *p*-value of 0.05.

RESULTS

Bony fusion

The fusion rate at 3 years or later following PLIF with TFC was 92%, based on the bony fusion criteria. When the fusion rate was analyzed according to preoperative bone marrow degeneration, it was 96.5% for no vertebral end plate degeneration, 80.8% for patients with Modic type 1, 83.6% with Modic type 2, and 54.5% with Modic type 3 (Fig. 2). The fusion rate of patients with Modic type 3 was significantly lower compared to those with other types (*p* < 0.05).

Two-hundred-fifty patients out of 259 patients with no vertebral end plate degeneration showed bony fusion on radiological study. Two patients showed halo around the

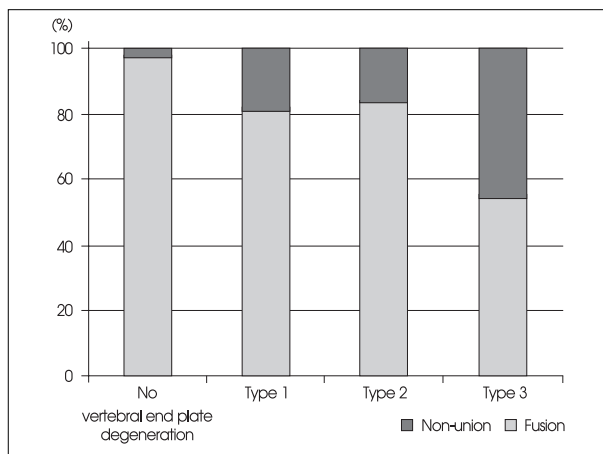


Fig. 2. Fusion rate by changes of vertebral end plate are shown. Fusion rate for patients with no end plate degeneration was 97%, 80.8% for patients with Modic type 1, 83.6% with Modic type 2, and 54.5% with Modic type 3. Modic type 3 shows a significantly low rate of fusion (*p* < 0.05).

cages and 7 patients did not show posterior bony bridge. Patients with Modic type 1, 5 patients were not compatible with bony fusion criteria. Out of 5 patients, 3 patients did not show posterior bony bridge, 1 patient showed an angular instability and 1 patient showed halo around the cages. Patients with Modic type 2, 9 patients were compatible with nonunion. Two patients showed both halo around the

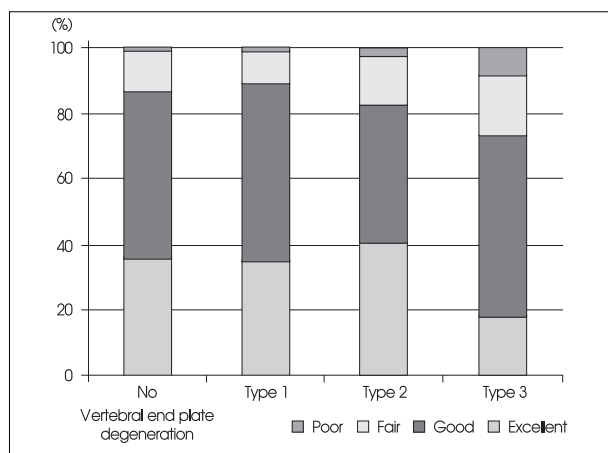


Fig. 3. Clinical and functional outcomes by Prolo's scale shows that the rate of excellent and good clinical outcome was 86% in patients with no vertebral end plate degeneration, 88.5% for patients with Modic type 1, 83.6% with Modic type 2, and 72.7% with Modic type 3. Modic type 3 shows a significantly low rate of clinical improvement ($p < 0.05$).

cages and angular instability. Three patients did not show posterior bony bridge, 2 patients showed angular instability alone, 1 patient showed halo around the cages and 1 patient showed traction formation. Patients with Modic type 3, 6 patients out of 11 patients were not compatible with bony fusion criteria. Four patients did not show posterior bony bridge and 2 patients showed instability on radiologic study.

Clinical success

As evaluated by follow-up studies for a mean of 59.8 months using Prolo's scale, the combined rate of excellent and good clinical outcome was 83.2%, while that of fair and poor efficacy was 16.8%. This finding indicates that the efficacy of PLIF using TFC is relatively high among these patients. According to the bone marrow degeneration, the clinical success rate for no end plate degeneration, Modic type 1, 2, 3, was 86.1%, 88.5%, 83.6%, and 72.7% respectively. The improvement rate was significantly lower among patients with Modic type 3 ($p < 0.05$) (Fig. 3).

Evaluating the clinical outcome with VAS score, patients with no vertebral end plate degeneration showed the decreased VAS score from 6.8 to 2.5 after operation. VAS score were decreased from 6.7 to 2.4 in Modic type 1, from 7.1 to 2.7 in Modic type 2 and from 7.0 to 3.8 in Modic type 3. VAS scores were decreased significantly in all groups, but Modic type 3 showed less improvement compare to other groups significantly ($p < 0.05$) (Fig. 4).

DISCUSSION

Various signal intensity changes of vertebral body marrow

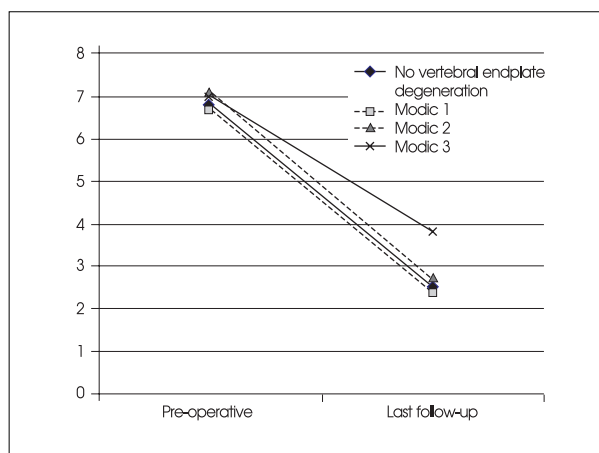


Fig. 4. Clinical outcomes by visual analog scale (VAS) are shown. Patients with no vertebral end plate degeneration decreased VAS score from 6.8 to 2.5 after operation. Patients with Modic type 1, 2, 3 decreased VAS score from 6.7, 7.1, 7.0 to 2.4, 2.7, and 3.8 respectively after operation. Modic type 3 shows lower decrease of VAS score significantly ($p < 0.05$).

adjacent to degenerative disc and endplates are often observed on MRI. These vertebral body marrow changes can be classified into three types. Type 1 changes showed low signal intensity on T1-weighted images and high signal intensity on T2-weighted images. Type 2 changes showed high signal intensity on T1-weighted images and isointense or slightly hyperintense signal on T2-weighted images. Type 3 changes demonstrated low signal intensity on both T1 and T2 weighted images^{15,16}.

Histopathology findings of type 1 vertebral end plate changes are disruption and fissuring of the endplate and vascularized fibrous tissues within the adjacent marrow. Endplate disruptions with lipid marrow replacement are shown in type 2 changes. Dense woven bone within the vertebral body can be found in type 3 changes which correlate extensive bony sclerosis on plain radiographs. Unlike type 3, type 1 and 2 changes show no definite correlation with sclerosis at radiography. However, clinical importance of vertebral endplate changes is not extensively known^{15,16}.

Although medical management (use of analgesics and anti-inflammatory agents) associated with external immobilization is obviously proposed for patients with vertebral end plate changes, arthrodesis has also been proposed and evaluated. Toyone et al.²³ reported that Modic type 1 patients tended to exhibit hypermobility and more low back pain, thus 17 of 37 patients underwent arthrodesis, while Modic type 2 changes were more common in patients with stable degenerative disc disease and patient tended to undergo surgery for radicular decompression (6 of 37 patients), thus they concluded that Modic type 1 signals are associated with instability and require arthrodesis more

commonly than Modic type 2 changes. Lang et al.¹²⁾ evaluated functional fusion stability in 33 patients who underwent arthrodesis. In 19 patients with solid fusion, they noted 16 cases of Modic type 2 changes. In 14 patients in whom nonunion was suspected, they observed 10 cases of Modic type 1 changes. They suggested that Modic type 1 in patients with unstable fusions might be related to reparative granulation tissue, inflammation, edema, and hyperemic changes while Modic type 2 in solid lumbar fusions might be related to marrow composition changes resulting from decreased biomechanical stress. Chataigner et al.⁸⁾ studied 56 patients who underwent anterior procedures with bone grafting for low back pain. Their best results were obtained in patients with Modic type 1 lesions. Results were poorer in patients who had black discs without endplate involvement or Modic type 2 lesions. Among 5 non-unions, 3 requiring posterior revision surgery were observed in Modic type 2 changes.

In the above mentioned literature, anterior lumbar interbody fusion or posterolateral fusion was performed in patients with chronic degenerative discs associated with vertebral end plate changes. However, we perform a PLIF procedure in which a cage was used. PLIF has certain benefits over conventional surgical methods, such as provision of wider and more familiar surgical fields, widening of collapsed disc height, sufficient decompression of nerve roots, and immediate post-operative stability. In addition, PLIF manifests load-sharing effects against the pressure of anterior vertebral column, thus promoting bone fusion^{2,10,13,14,17,21)}.

In the current study, the fusion rate was 80.8% for patients with Modic type 1 changes, 83.6% with Modic type 2 changes, and 54.5% with Modic type 3 changes. The fusion rate of patients with Modic type 3 changes was significantly lower compared to those in other groups ($p < 0.05$). Modic type 1 degenerative lesions correspond to edema of vertebral endplates and subchondral bone that could correspond to microfractures of the cancellous bone and endplate cracks accompanied by increased vascular density along with an increase in the number of nerve endings and levels of proinflammatory chemical mediators^{6,22)}. These vascular and inflammatory phenomena follow the initial mechanical phenomena. There is a possibility that Modic type 1 lesions are replaced by Modic type 2 lesions, which correspond to a globally less disabling state in terms of low back pain. Intermediate stages sometimes can be seen between Modic type 1 and 2 lesions, tending to confirm the hypothesized natural history for such lesions. Modic type 3 or sclerotic stage, which is much rarer than Modic types 1 or 2, probably corresponds to a state close to natural fusion. It is necessary to perform additional fusion

procedure, such as pedicle screw fixation, in patients with Modic type 3 degeneration.

This study has important limitation which the numbers in the type 3 Modic changes group are too small to extrapolate conclusion from and retrospective study design. However, current study suggests that pre-operative type 3 Modic changes can be an important factor of non-union after PLIF.

CONCLUSION

Vertebral end-plate changes demonstrated by MRI had a relatively high incidence (26.6%) in chronic degenerative disc disease. Among them, Modic type 2 degeneration was most common (15.7%). PLIF procedures in which TFC used in patients with Modic type 1 and 2 showed an acceptably high success and fusion rate. Modic type 3, however, had a poor success and fusion rate, 82.7% and 54.5% respectively. A preoperative MRI evaluation for vertebral end-plate changes is mandatory.

In conclusion, the presences of Modic type 1 and 2 signals appear to constitute a reasonable posterior fusion indication. In contrast, Modic type 3 lesions do not appear to constitute a good indication for posterior fusion. Additional fusion procedures should be undertaken in Modic type 3 degeneration. Otherwise, a fusion procedure should not be performed for Modic type 3 degeneration

References

1. Albert HB, Manniche C : Modic changes following lumbar disc herniation. *Eur Spine J* 16 : 977-982, 2007
2. Barrick WT, Schofferman JA, Reynolds JB, Goldthwaite ND, McKeehen M, Keaney D, et al. : Anterior lumbar fusion improves discogenic pain at levels of prior posterolateral fusion. *Spine (Phila Pa 1976)* 25 : 853-857, 2000
3. Boden SD, Davis DO, Dina TS, Patronas NJ, Wiesel SW : Abnormal magnetic-resonance scans of the lumbar spine in asymptomatic subjects. A prospective investigation. *J Bone Joint Surg Am* 72 : 403-408, 1990
4. Boos N, Rieder R, Schade V, Spratt KF, Semmer N, Aebi M : 1995 Volvo Award in Clinical Sciences. The diagnostic accuracy of magnetic resonance imaging, work perception, and psychosocial factors in identifying symptomatic disc herniations. *Spine (Phila Pa 1976)* 20 : 2613-2625, 1995
5. Braithwaite I, White J, Saifuddin A, Renton P, Taylor BA : Vertebral end-plate (Modic) changes on lumbar spine MRI : correlation with pain reproduction at lumbar discography. *Eur Spine J* 7 : 363-368, 1998
6. Brisby H, Olmarker K, Larsson K, Nutu M, Rydevik B : Proinflammatory cytokines in cerebrospinal fluid and serum in patients with disc herniation and sciatica. *Eur Spine J* 11 : 62-66, 2002
7. Buttermann GR, Heithoff KB, Ogilvie JW, Transfeldt EE, Cohen M : Vertebral body MRI related to lumbar fusion results. *Eur Spine J* 6 : 115-120, 1997
8. Chataigner H, Onimus M, Polette A : [Surgery for degenerative lumbar disc disease. Should the black disc be grafted?] *Rev Chir*

- Orthop Reparatrice Appar Mot** 84 : 583-589, 1998
9. Fritzell P, Hägg O, Wessberg P, Nordwall A; Swedish Lumbar Spine Study Group : 2001 Volvo Award Winner in Clinical Studies : Lumbar fusion versus nonsurgical treatment for chronic low back pain : a multicenter randomized controlled trial from the Swedish Lumbar Spine Study Group. **Spine (Phila Pa 1976)** 26 : 2521-2532; discussion 2532-2534, 2001
 10. Groth AT, Kuklo TR, Klemme WR, Polly DW, Schroeder TM : Comparison of sagittal contour and posterior disc height following interbody fusion : threaded cylindrical cages versus structural allograft versus vertical cages. **J Spinal Disord Tech** 18 : 332-336, 2005
 11. Jensen MC, Brant-Zawadzki MN, Obuchowski N, Modic MT, Malkasian D, Ross JS : Magnetic resonance imaging of the lumbar spine in people without back pain. **N Engl J Med** 331 : 69-73, 1994
 12. Lang P, Chafetz N, Genant HK, Morris JM : Lumbar spinal fusion. Assessment of functional stability with magnetic resonance imaging. **Spine (Phila Pa 1976)** 15 : 581-588, 1990
 13. Lee CK, Vessa P, Lee JK : Chronic disabling low back pain syndrome caused by internal disc derangements. The results of disc excision and posterior lumbar interbody fusion. **Spine (Phila Pa 1976)** 20 : 356-361, 1995
 14. Lin PM, Cautilli RA, Joyce MF : Posterior lumbar interbody fusion. **Clin Orthop Relat Res** : 154-168, 1983
 15. Modic MT, Ross JS : Lumbar degenerative disk disease. **Radiology** 245 : 43-61, 2007
 16. Modic MT, Steinberg PM, Ross JS, Masaryk TJ, Carter JR : Degenerative disk disease : assessment of changes in vertebral body marrow with MR imaging. **Radiology** 166 : 193-199, 1988
 17. Mulholland RC, Sengupta DK : Rationale, principles and experimental evaluation of the concept of soft stabilization. **Eur Spine J** 11 Suppl 2 : S198-S205, 2002
 18. Prolo DJ, Oklund SA, Butcher M : Toward uniformity in evaluating results of lumbar spine operations. A paradigm applied to posterior lumbar interbody fusions. **Spine (Phila Pa 1976)** 11 : 601-606, 1986
 19. Ray CD : Threaded titanium cages for lumbar interbody fusions. **Spine (Phila Pa 1976)** 22 : 667-679; discussion 679-680, 1997
 20. Stadnik TW, Lee RR, Coen HL, Neiryneck EC, Buisseret TS, Osteaux MJ : Annular tears and disk herniation : prevalence and contrast enhancement on MR images in the absence of low back pain or sciatica. **Radiology** 206 : 49-55, 1998
 21. Sudo H, Oda I, Abumi K, Ito M, Kotani Y, Minami A : Biomechanical study on the effect of five different lumbar reconstruction techniques on adjacent-level intradiscal pressure and lamina strain. **J Neurosurg Spine** 5 : 150-155, 2006
 22. Takahashi H, Suguro T, Okazima Y, Motegi M, Okada Y, Kakiuchi T : Inflammatory cytokines in the herniated disc of the lumbar spine. **Spine (Phila Pa 1976)** 21 : 218-224, 1996
 23. Toyone T, Takahashi K, Kitahara H, Yamagata M, Murakami M, Moriya H : Vertebral bone-marrow changes in degenerative lumbar disc disease. An MRI study of 74 patients with low back pain. **J Bone Joint Surg Br** 76 : 757-764, 1994
 24. Weishaupt D, Zanetti M, Hodler J, Boos N : MR imaging of the lumbar spine : prevalence of intervertebral disk extrusion and sequestration, nerve root compression, end plate abnormalities, and osteoarthritis of the facet joints in asymptomatic volunteers. **Radiology** 209 : 661-666, 1998