

De novo interstitial direct duplication 8 (p21.3p23.1) with Pierre Robin sequence

Soon Min Lee, M.D., Min Soo Park, M.D., Kook In Park, M.D.
Ran Namgung, M.D., Chul Lee, M.D., Jin Seong Lee, M.D.*
Kyung A Lee, M.D.[†] and Jong-Rak Choi, M.D.[†]

Department of Pediatrics, Clinical Genetics*, and Laboratory Medicine[†]
Yonsei University College of Medicine, Seoul, Korea

= Abstract =

The Pierre Robin sequence (PRS) is the nonrandom association of micrognathia, cleft palate, and glossoptosis, leading to respiratory and feeding difficulties that appear neurogenic rather than mechanical in causation. Genetic determinants are thought to underlie this functional and morphological entity, based on the existence of Mendelian syndromes with PRS. Here, we demonstrate the association of PRS with trisomy 8p due to duplication of a segment as the karyotype 46,XX,dup(8)(p21.3p23.1) and confirm the additional materials as chromosome 8 via whole chromosome paint probes. Our observation supports the hypothesis regarding a genetic basis for nonsyndromic PRS, strengthens the possible genetic association with isolated cleft palate, and provides a candidate PRS locus in chromosomal region 8(p21.3p23.1). (*Korean J Pediatr* 2009;52:603-606)

Key Words : Duplication, Pierre Robin sequence, Trisomy 8p

Introduction

The Pierre Robin syndrome (PRS) is a congenital anomaly characterized by cleft palate (CP) and micrognathia that result in glossoptosis, which was first described by Robin (1923) as the tongue tending to obstruct the airway and causing feeding and respiratory difficulties during the early postnatal period¹⁾. Although no genetic locus is confirmed for PRS, genetic factors are thought to play a role in this functional and morphological entity. The arguments are based on a substantial number of well-delineated Mendelian syndromes that may associated with PRS and the observation of familial PRS. Many reports noted deletions, duplications, translocations, and mutations involved in chromosomes 1 to 6, 10 to 13, and 16 to 18 were associated with PRS. Especially regions in chromosome 2 (2q24.1-33.3), chromosome 4 (4q32- qter), chromosome 11 (11q21-q23.1), and chromosome 17 (17q21-q24.3) were highly associated

with PRS²⁾. There is no reported case of PRS associated with chromosome 8.

In this report, clinical and cytogenetic findings showing a PRS with a de novo structural rearrangement of chromosome 8 are presented.

Case report

A full-term newborn girl was initially transferred for feeding and respiratory difficulty. She was born at 37 weeks of gestation, by cesarean section. At the time of conception, the mother was 34 years old and the father was 37 years old. Family history was unremarkable; one elder sister showed no anomaly. Her birth weight was 2,800 g (25-50th percentile), length was 46 cm (25th percentile), and head circumference was 33 cm (50th percentile). Apgar scores were 7 at 1 min, and 8 at 5 min.

External examination showed severe micrognathia, glossoptosis, and a posterior cleft of the soft palate and the posterior third of the hard palate corresponding to PRS. The distance between the upper and lower alveolar process in the sagittal plane was 2 cm. The eyes showed normal appearance without ocular malformation. The ear setting and external ear canals were normal. The hands and feet were nor-

Received : 16 September 2008, Revised : 17 November 2008

Accepted : 2 December 2008

Address for correspondence : Jong-Rak Choi, M.D.

Department of Laboratory Medicine, Yonsei University College of Medicine,
250 Seongsanno, Seodaemun-Gu, Seoul, Korea

Tel : +82.2-2228-5900, Fax : +82.2-3461-9473

E-mail : cjr@yumc.yonsei.ac.kr

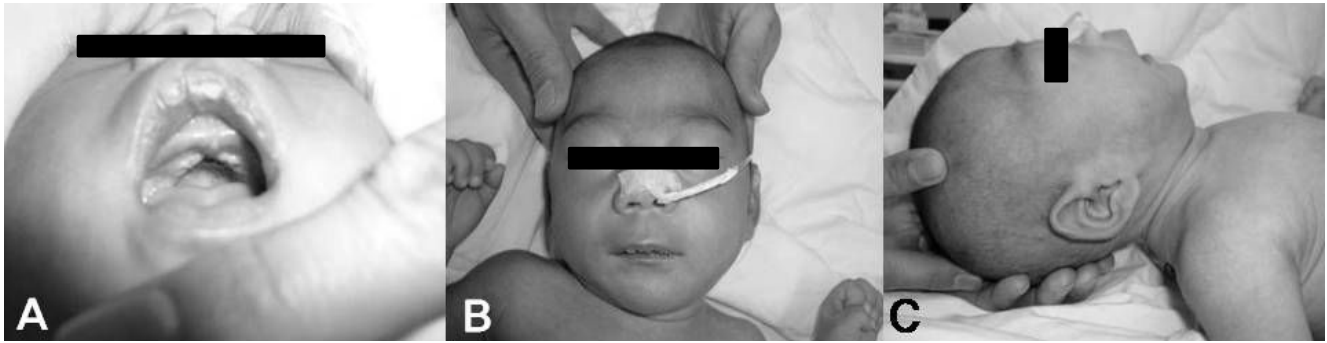

Fig. 1. (A) Unusual round-shaped palatal cleft with incomplete closure of the palate secondary to posterior displacement of the tongue. (B) Frontal view of the face. (C) Lateral view of the face.

mally positioned. The external genitalia were normal (Fig. 1). The skeletal X-rays showed no anomalies.

Internal examination showed all internal organs in their normal anatomic positions and without malformations. Abdominal ultrasonography showed normal liver echo-texture without focal lesion, normal biliary system, both kidneys, spleen, and pancreas. Brain MRI showed corpus callosal thinning and cavum septum pellucidum, but no intracranial abnormality was revealed. Cardiac echocardiography showed no cardiac abnormality and normal coronary pattern except for compression of right ventricle and left atrium due to pectus excavatum and mild dynamic RVOT obstruction (dP= 18 mmHg). The ophthalmologic exam showed no abnormality.

Laboratory studies showed no prominent abnormality in terms of diagnosing any specific metabolic disease.

The newborn girl had a feeding difficulty due to the tongue tending to obstruct the airway, and a nasogastric feeding tube was used. She was prepared for oroplastic surgery for micrognathia reconstruction.

1. Cytogenetic Studies

Standard GTG-banding analysis was performed on metaphase obtained from PHA-stimulated, synchronized lymphocytes according to standard procedures³. The karyotypes were described according to the International System for Cytogenetic Nomenclature (ISCN 2005)⁴. G-banding of chromosomes derived from the patient's lymphocyte showed partial duplication of the short arm of chromosome 8 from band p21 to p23 with karyotype 46, XX, dup(8)(p21.3p23.1) (Fig. 2). This was interpreted as a net imbalance of trisomy 8p. Examination of peripheral blood lymphocytes obtained from the patient's parents showed normal karyotypes, indicating de

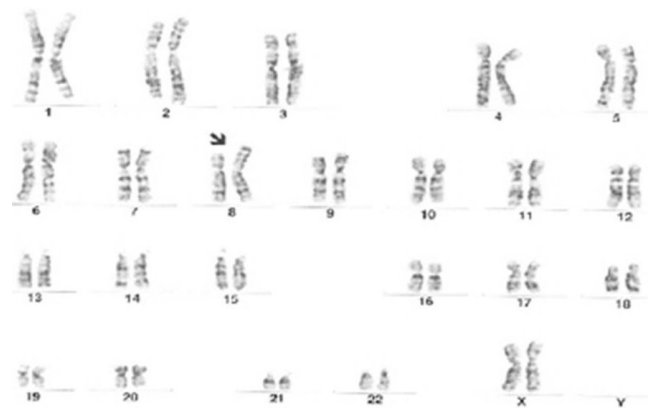


Fig. 2. Karyotyping showing duplication of chromosome 8(p21.3p23.1) in the patient.

novo origin of the additional chromosomal material.

To better identify chromosomal rearrangement, FISH analysis has to be performed using Whole Chromosome Paint 8 (WCP) Probes supplied by Vysis (Downers Grove, IL). Representative cell images were captured using a computer-based imaging system (MetaSystems, Altlußheim, Germany). Twenty-six cells were analyzed for each metaphase spread prepared from the proband. Single and double-color FISH experiments were performed on chromosome preparations. WCP for chromosome 8 revealed the chromosome 8 materials hybridized to the marker chromosome in the metaphase cells identified by FISH (Fig. 3), as well as to the normal chromosome 8. This finding confirmed the additional material (arrow head) was derived from chromosome 8. A segment from chromosome 8 was inserted into the short arm of chromosome 8(p21.3p23.1). Whether this was an inverted or direct duplication with or without concomitant microdeletion has not been determined.

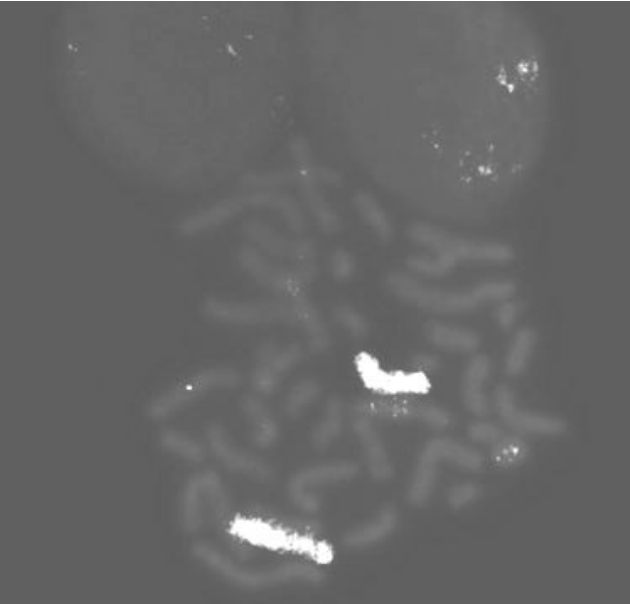


Fig. 3. Fluorescent *in-situ* hybridization (FISH) of the rearranged chromosomes in the same metaphase cell showing the WCP hybridized to the marker area and the normal chromosome 8.

Discussion

To our knowledge this is the first report showing an association of duplication 8(p21.3p23.1) with PRS. Several patients with partial trisomy of the short arm of chromosome 8 have been documented, mainly resulting from a parental translocation, and rarely from de novo duplication⁵. Previous reviews described the clinical picture of patients with inverted duplication 8p as a recognizable multiple congenital anomaly and mental retardation syndrome. The clinical phenotype of multiple anomalies is characterized by craniofacial abnormalities such as macrostomia, deep set eyes, hypertelorism with broad nasal root, everted lower lip, large soft ears, high-arched palate, cleft palate (CP), short neck, and limb abnormality including camptodactyly and flexion contractures of the hands and legs^{5, 6}. In the present case, the patient had only CP, micrognathia and glossoptosis. The brain imaging showed corpus callosal thinning and cavum septum pellucidum but no specific syndrome is associated.

PRS associates with micrognathia and retroposition of the mandible, glossoptosis, and a cleft of the soft palate, leading to upper airway obstruction and respiratory and feeding difficulties of variable intensities in newborns. Even though the clinical entity is well defined, the pathophysiology of PRS

is not clearly understood and is likely heterogeneous. PRS is considered as a consequence of an early deficiency of rhombencephalic neurulation leading to velopalatal division and micrognathia secondary to a lingual motility disturbance⁷. A recent neurophysiological study in isolated PRS suggests it is a dysfunction of the tongue and pharynx motor organization without structural change in brainstem nuclei and pathways⁸. Alternatively, a primary defect of the closing palatine shelves, such as in Stickler syndrome, cannot be excluded.

The overall incidence of PRS is low: 1 per 8,500 to 14,000 births in the general population⁹. The prevalence of PRS is the same in both sexes. Several factors point to a genetic etiology of PRS. Patients with PRS often have other family members with a cleft lip or palate (13.0%, 27.7%) and PRS is often present in other syndromes such as Stickler syndrome, velocardiofacial syndrome, Marshall syndrome, Treacher Collins syndrome, Catel-Mancke syndrome, Kabuki syndrome, Nager syndrome, and teratogene syndromes⁴.

A comparison among cases in the literature and in cytogenetic databases of PRS revealed consistency to a certain degree to chromosomes 1 to 6, 10 to 13, and 16 to 18, especially to loci 2q24.1–33.3, 4q32–qter, 11q21–23.1, and 17q21–24.3, respectively. This rationale is the basis for PRS being acknowledged as a possible Mendelian entity (MIM 261800), alongside nonsyndromic CP (MIM 119540)². In these families, the broad clinical variability observed, ranging from bona fide PRS to isolated CP, suggests a few of the genetic determinants for nonsyndromic CP could underlie sporadic or familial PRS. A search in MCNdb (<http://www.mcndb.org/>)

on "robin" and "pierre robin" revealed six cases on chromosomes 2 (2q32 and 2q33) and 17 (17q21 and 17q24)². There is no reported case associated with chromosome 8.

A number of researchers found CP to be significantly associated ($P < 0.05$) with deletions in 2q32, 4p16–13, and 4q31–35 and duplications in 3p24–23, 3p26, 3q23–25, 7q22–32, 8q21, 10p15–11, 14q11–21, 16p12–13, and 22q12–13¹⁰. Micrognathia was found to be significantly associated ($P < 0.05$) with deletions in 4p16–14, 4q31–35, 6q25–27, and 11q23 and duplications in 10q24 and 18q12–23^{10, 11}.

In this report, clinical and cytogenetic findings showed a PRS with a de novo structural rearrangement of chromosome 8. The data presented suggest a number of PRS cases may also originate from mutation of a gene localized to a region on chromosome 8(p21.3p23.1). Further studies involving cyto-

genetic analyses and mutation analyses of candidate genes in PRS are needed.

한 글 요약

De novo interstitial direct duplication 8(p21.3p23.1)을 보인 Pierre Robin sequence 1예

연세대학교 의과대학 소아과학교실, 임상유전학교실*
진단검사의학교실†

이순민 · 박민수 · 박국인 · 남궁란
이철 · 이진성* · 이경아† · 최종락†

Pierre Robin sequence (PRS)는 소악중, 구개열, 설하수 및 고궁 구개 등의 기형을 합병한 선천성 질환으로, 수유 장애 및 호흡 곤란 소견을 보이는 증후군이다. PRS과 관련된 염색체 핵형 분석 결과가 보고되면서, 유전학적 관련성이 제시되어 왔으나, 아직까지 명확히 규명되지 않은 상태이다. 이에 저자들은 PRS 환아에서 처음으로 핵형 46, XX, dup(8)(p21.3p23.1)를 보인 환아를 경험하고, 전염색체탐색자 분석을 통해 중복된 물질이 8번 염색체임을 확인하였으며, PRS와 8번 삼염색체성과의 관련성을 보고하는 바이다.

References

1) Robin P. Backward lowering of the root of the tongue causing respiratory disturbance. Bull Acad Natl Med 1923;89:37-41.

- 2) Jakobsen LP, Knudsen MA, Lespinasse J, García Ayuso C, Ramos C, Fryns JP, et al. The genetic basis of the Pierre Robin Sequence. Cleft Palate Craniofac J 2006;43:155-9.
- 3) ISCN 2005. An international system for human cytogenetic nomenclature. Shaffer LG, Tommerup N: Karger, Basel.
- 4) Verma RS, Babu A. Human Chromosomes: Manual of basic technique. 1st ed. New York: Pergamon Press, 1989:4-51
- 5) Moog U, Engelen JJ, Albrechts JC, Baars LG, de Die-Smulders CE. Familial dup(8)(p12p21.1): mild phenotypic effect and review of partial 8p duplications. Am J Med Genet 2000; 94:306-10.
- 6) de Die-Smulders CE, Engelen JJ, Schrandt-Stumpel CT, Govaerts LC, de Vries B, Vles JS, et al. Inversion duplication of the short arm of chromosome 8: clinical data on seven patients and review of the literature. Am J Med Genet 1995; 59:369-74.
- 7) Couly G, Cheron G, de Blic J, Despres C, Cloup M, Hubert P. The Pierre-Robin syndrome. Classification and new therapeutic approach. Arch Fr Pediatr 1988;45:553-9.
- 8) Renault F, Flores-Guevara R, Soupre V, Vazquez MP, Baudon JJ. Neurophysiological brainstem investigations in isolated Pierre Robin sequence. Early Hum Dev 2000;58:141-52.
- 9) Bush PG, Williams AJ. Incidence of the Robin anomalad (Pierre Robin syndrome). Br J Plast Surg 1983;36:434-7.
- 10) Brewer C, Holloway S, Zawalnyski P, Schinzel A, FitzPatrick D. A chromosomal deletion map of human malformations. Am J Hum Genet 1998;63:1153-9.
- 11) Brewer C, Holloway S, Zawalnyski P, Schinzel A, FitzPatrick D. A chromosomal duplication map of malformations: regions of suspected haplo- and triplolethality-and tolerance of segmental aneuploidy-in humans. Am J Hum Genet 1999;64: 1702-8.