

The Efficacy of Hepatic Resection after Neoadjuvant Transarterial Chemoembolization (TACE) and Radiation Therapy in Hepatocellular Carcinoma Greater Than 5 cm in Size

In cases of large hepatocellular carcinoma (HCC), neoadjuvant treatment such as transarterial chemoembolization (TACE) and radiation therapy can be performed. The aim of this study was to evaluate the outcome of these treatments prior to hepatic resection. Between January 1994 and May 2007, 16 patients with HCC greater than 5 cm in size were treated with TACE and radiation therapy prior to hepatic resection. The clinicopathologic factors were reviewed retrospectively. Of the 16 patients, there were 14 men and two women, and the median age was 52.5 yr. TACE was performed three times in average, and the median radiation dosage was 45 Gy. The median diameter of tumor on specimen was 9.0 cm. The degree of tumor necrosis was more than 90% in 14 patients. The median survival time was 13.3 months. Five patients had survived more than 2 yr and there were two patients who had survived more than 5 yr. Although the prognosis of large HCC treated with neoadjuvant therapy is not satisfactory, some showed long-term survival longer than 5 yr. Further research will be required to examine the survival and disease control effect in a prospective randomized study.

Key Words : Carcinoma, Hepatocellular; TACE; Radiotherapy; Hepatic Resection

Sae Byeol Choi, Kyung Sik Kim,
Young Nyun Park*, Jin Sub Choi,
Woo Jung Lee, Jinsil Seong¹,
Kwang-Hyub Han¹, and Jong Tae Lee³

Departments of Surgery, Pathology*, Radiation
Oncology¹, Internal Medicine², and Radiology³,
Severance Hospital, Liver Cancer Special Clinic
Yonsei University College of Medicine, Seoul, Korea

Received : 11 April 2008
Accepted : 29 June 2008

Address for correspondence

Kyung Sik Kim, M.D.
Department of Surgery, Yonsei University College of
Medicine, 250 Seongsan-ro, Seodaemun-gu, Seoul
120-752, Korea
Tel : +82.2-2228-2125, Fax : +82.2-313-8289
E-mail : kskim88@yuhs.ac

INTRODUCTION

Hepatocellular carcinoma (HCC) is the fifth most common malignancy in the world (1) and the third most common cause of death due to cancer in Korea (2). Multiple treatment modalities are available for patients with HCC, and hepatic resection has been successful as a treatment option with curative intent (3). However, more than 80% of patients are not candidates for surgical resection at the time of diagnosis due to advanced lesions and/or associated liver disease (4). In those cases, clinicians are confronted with the difficulty of selecting the optimal treatment option. The usual goals of the neoadjuvant therapy are to eradicate subclinical disease to reduce recurrence and the tumor bulk to prevent tumor spillage during operation. In the cases of large HCC greater than 5 cm in size, neoadjuvant treatments such as transarterial chemoembolization (TACE) and radiation therapy can be performed.

Initially, TACE was performed to treat unresectable HCC (5). Recently, TACE has been used as preoperative adjuvant therapy in patients with resectable HCC in the hope of increasing disease-free survival rates and improving long-term results after hepatectomy (6, 7). In those cases, however, the efficacy of improving postoperative survival remains controversial. Moreover, TACE alone frequently results in incom-

plete tumor necrosis (8).

Radiation therapy alone has been of limited benefit in the treatment of HCC. However, in several reports showing the results of HCC with combined treatment of radiation and chemotherapy, a beneficial effect has been suggested (9, 10).

Currently, surgical resection of advanced HCC following neoadjuvant treatment is challenging with the development of surgical techniques. Furthermore reductive or salvage surgery that resulted in the downstaging of unresectable HCC following palliative treatment showed some benefits for survival (11, 12). For large HCC, efforts to increase the curative rate and survival will be important in the search for various therapeutic modalities.

The efficacy of preoperative TACE and radiation therapy prior to hepatic resection has not been extensively reported. In this retrospective study, we analyzed sixteen patients with HCC greater than 5 cm in size that underwent hepatic resection after neoadjuvant combined TACE and radiation therapy.

MATERIALS AND METHODS

Between January 1994 and May 2007, 436 patients with HCC underwent hepatic resection. Among these patients, 16 patients with HCC of greater than 5 cm in size were given

preoperative TACE and radiation therapy prior to hepatic resection at Severance Hospital, Yonsei University College of Medicine in Seoul, Korea. Medical records, histopathology, and survival data were reviewed and analyzed retrospectively.

TACE and radiation therapy were carried out as described below. TACE was performed with an infusion of a mixture of 5 mL iodized oil contrast medium (Lipiodol, Guerbet, Aulnay-sous-Bois, France) and 50 mg Adriamycin (Adriamycin, Ildong pharm, Seoul, Korea) and followed by embolization using gelatin sponge particles (Cutanplast, Maschia Bruneili Spa, Milano, Italy).

Patients that received radiation therapy in the primary lesion of the liver were included in the study, whereas patients who received radiation therapy in the extrahepatic metastatic organs were excluded. Simulating computed tomography (CT) scans were taken to determine the radiation volume for each patient, including the tumors with 2-3 cm margin.

We investigated the effect of preoperative TACE and radiation therapy through the reduction of the tumor size. We also evaluated the level of alpha-fetoprotein (AFP), Indocyanine Green retention rate at 15 min (ICG-R 15), Child-Pugh classification, operative factors, and pathologic results-tumor size and number, the presence of vessel invasion, the extent of tumor necrosis, and resection margin and stage according to the Japanese TNM classification (13).

The effectiveness of preoperative therapy on tumor response was evaluated by comparing serial CT scans before and after treatment. The response evaluation criteria in solid tumors (RECIST) (14) was used for evaluation of the tumor response. The RECIST uses unidimensional measurement. Complete disappearance of the tumor was considered as a complete response (CR). A reduction of at least 30% in the sum of the longest diameters of target lesions, taking as reference the baseline study, was considered a partial response (PR). An increase of at least 20% in the sum of the longest diameters of target lesions, taking as reference the smallest sum of the longest diameters recorded since treatment started or new lesions appeared, was regarded as a progressive disease (PD). However, neither the PR nor PD criteria were met, taking as reference the smallest sum of the longest diameters recorded since treatment started was regarded as a stable disease (SD). All patients received anatomical hepatic resections with the goal of achieving negative resection margins. In most patients, however, due to the cirrhosis and liver atrophy accompanied by huge liver mass, the achievement of enough resection margins being greater than 1 cm was difficult.

Patients were followed up at 1 month after operation and then every 3 months. Patients were screened for AFP, and they underwent dynamic CT. When intrahepatic recurrence was suspected, most of the patients underwent hepatic angiography or magnetic resonance imaging (MRI) to confirm the existence of recurrence.

Statistical calculations were performed using SPSS, version

13.0 for Windows (SPSS Inc. Chicago, IL, U.S.A.). Overall survival and recurrence rates were calculated using the Kaplan-Meier method.

RESULTS

The 16 patients examined in the study included 14 men and two women with a median age of 52.5 yr (ranging from 22-70 yr). The clinicopathological characteristics of the 16 patients are shown in Table 1. Fifteen patients had hepatitis B viral infection and 1 patient had hepatitis C viral infection. Median numbers of TACE performed preoperatively was three times and median radiation dosage was 45 Gy (with a range of 30-68 Gy). The median interval between the ter-

Table 1. Clinicopathological characteristics

Factor	
Sex (M:F)	14:2
Age (yr)	52.5* (22-70)
Preoperative AFP (IU/mL)	13.1* (2.0-2,648.0)
Preoperative ICG R15 (%)	12.7* (1.0-22.7)
Clinical stage [†] (Japanese TNM)	
II	13
III	3
No of TACE (times)	3* (1-6)
Radiation dosage (Gy)	45* (30-68)
Response (patients)	
CR	0
PR	2
SD	11
PD	3
Time interval to operation (month)	4.7* (0.6-39.1)
Operative time (min)	275* (175-630)
Blood loss (mL)	1,000* (96-6,000)
No of tumors	
1	13
2	2
3	1
Degree of necrosis	
100%	10
90-95%	4
80%	1
30%	1
Resection margin (cm)	
<0.5	8
0.5-1	3
≥ 1	5
Pathological stage (Japanese TNM)	
II	10
III	4
IV A	2

*, Median value; [†], This clinical staging was done after neoadjuvant therapy, just before liver resection.

AFP, alpha-fetoprotein; ICG R15, indocyanine green retention rate at 15 min; TACE, transarterial chemoembolization; CR, complete response; PR, partial response; SD, stable disease; PD, progressive disease.

mination of radiation therapy and hepatic resection was 4.7 months. The median tumor diameter before the neoadjuvant therapy measured on the CT scans was 10.0 cm (with a range of 6.3-18.0 cm). Changes in tumor size comparing the CT scans before and after the treatment were following: size reduction was achieved in nine cases, an increase in tumor size was noted in three cases, and four cases displayed no change. None of the 16 patients demonstrated a CR, and only two patients showed a PR according to RECIST criteria. The response rate calculated for the proportion of CR and PR to 16 patients was 12.5% in preoperative CT scan.

All patients belonged to Child-Pugh class A before and after treatment. The median ICG-R 15 (preoperative status) was 12.7% (and ranged from 1.0-22.7%). Seven patients showed elevation of ICG-R 15 after treatment (ICG-R15 was not checked at initial diagnosis in three patients). The median value of AFP at initial diagnosis was 1,507.3 IU/mL (with a range from 4.4 to >50,000 IU/mL). The median value of AFP after treatment (just preoperative status) was 13.1 (with a range from 2.0 to 2,648 IU/mL). Thirteen patients demonstrated more than 50% decrease of AFP levels after treatment. Two patients demonstrated elevation of AFP levels after treatment.

Various surgical procedures were performed, including right hemihepatectomy (n=8), left hemihepatectomy (n=4), central bisectionectomy (n=1), trisegmentectomy (n=1) and bisegmentectomy (n=2). In the cases of large tumors combined with severe adhesion making difficulties in liver mobilization, anterior approach rather than conventional technique of liver mobilization was performed.

Thirteen of 16 patients had a single tumor. The median

tumor diameter measured on the specimen was 9.0 cm (with a range of 5-18 cm). The degree of tumor necrosis noted upon microscopic examination was more than 80% necrosis in 15 patients. Microvessel invasion was detected in five patients. The pathology of the remaining liver was characterized as normal in three patients, as chronic hepatitis in eight patients, and as cirrhosis in five patients. Ten patients had pathological stage II tumors, four patients had stage III tumors, and two patients had stage IVA tumors according to Japanese TNM system. Finally, the staging discrepancies were noted between the clinical and pathological stages in five patients whose tumor stages were upgraded due to microvessel invasion.

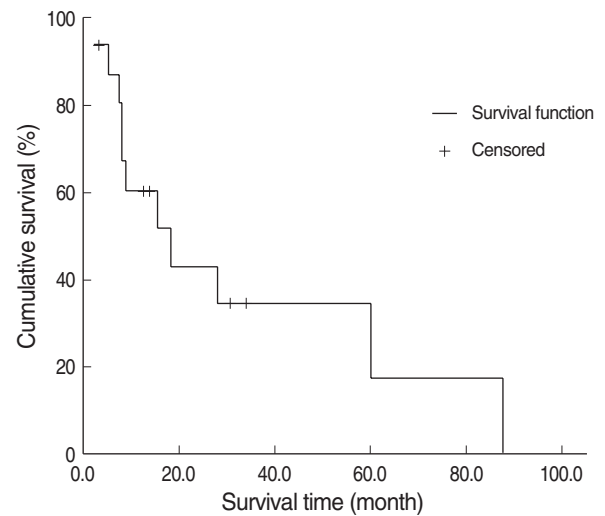


Fig. 1. Overall survival curve of the 16 patients.

Table 2. The clinicopathological characteristics and survival of 16 patients

Case	Sex	Age	No of TACE	RTx dose (cGy)	AFP* (IU/mL)	AFP† (IU/mL)	ICG R15 (%)	Response	No of tumor	Necrosis (%)	Resection margin (cm)	Recur-rence	Disease-free survival (month)	Survival	Survival time (month)
1	M	44	3	5,040	8,688	19.61	14.8	SD	1	99	0.7	Yes	3.7	No	7.4
2	M	58	6	4,500	>50,000	90.19	15.0	SD	1	99	0.2	Yes	2.7	No	18.2
3	M	54	1	5,940	4,506	133	12.0	SD	2	99	1.3	Yes	3.1	No	15.6
4	F	46	1	4,500	23,189.4	59.1	11.8	SD	1	99	2.0	Yes	30.4	No	87.4
5	M	22	1	3,000	184	2.3	8.1	PD	1	99	0.3	Yes	3.4	No	8.0
6	F	46	3	6,840	3,929.2	2	5.9	SD	1	99	0.1	No	3.0	No	3.0
7	M	70	4	4,500	2,826	1,874	13.4	SD	3	30	0.25	Yes	7.7	No	28.0
8	M	46	4	4,500	>50,000	2,648	8.8	SD	2	90	0	Yes	0.9	No	5.0
9	M	63	4	5,400	4.4	11.97	13.4	SD	1	99	2.0	No	59.9	No	60.0
10	M	66	5	4,500	188.6	21.67	8.3	SD	1	90	0.5	Yes	2.0	No	9.0
11	M	54	2	5,400	61.36	2.73	14.0	PD	1	99	0.3	No	7.8	No	7.8
12	M	52	2	4,500	6.47	12.85	22.7	SD	1	80	1.0	Yes	15.5	Yes	33.1
13	M	51	3	4,500	91.31	13.44	22.1	PD	1	90	0	No	13.7	Yes	13.7
14	M	35	4	4,500	7,423.94	3.49	19.4	PR	1	99	0.3	No	11.0	Yes	11.0
15	M	58	1	4,500	15.23	2.1	4.4	SD	1	95	0.7	No	30.5	Yes	30.5
16	M	53	1	4,500	22.35	11.9	1.0	PR	1	99	3.0	No	3.0	Yes	3.0

*, AFP level at initial diagnosis; †, AFP level after TACE and radiation therapy.

TACE, transarterial chemoembolization; AFP, alpha-fetoprotein; ICG R15, indocyanine green retention rate at 15 min; SD, stable disease; PD, progressive disease; PR, partial response.

No postoperative mortality occurred in the cases reviewed in this study. The mean follow-up period was 24.2 months (with a range of 3.2-87.4 months) (Fig. 1). The median survival time was 13.3 months. The median disease-free survival time was 5.7 months. The patterns of recurrence were intrahepatic (n=7) and lung (n=2), and most recurrences occurred within 4 months of the operation. Eleven patients died due to tumor recurrences (n=8) and hepatic failure (n=2). Five patients survived more than 2 yr, and 2 patients survived more than 5 yr (Table 2). The two long-term survivors showed complete total necrosis of the tumor although 1 patient showed vascular invasion of the necrotic tumor. The pathology of remaining liver showed non-cirrhotic liver.

DISCUSSION

Several treatment modalities are available for patients with HCC, including TACE, radiofrequency ablation, hepatic arterial infusion, and radiation therapy. When adequate neoadjuvant treatment is achieved, sequential hepatic resection may be a valuable option for prolonging survival. However, the main problem with these tumor-shrinking treatments is that only a small proportion of patients respond well enough to allow hepatic resection following therapy, and the responders cannot be predicted.

The efficacy of salvage or reductive surgery for HCC following adjuvant therapy has been reported by several authors (11, 12, 15). Nevertheless, the efficacy of preoperative TACE is controversial. Some authors have demonstrated the adverse effects of preoperative TACE (16, 17), while others have reported its efficacy (7, 18). The main limitation of TACE is incomplete necrosis due to dual blood supply around the capsule, multiple collateral circulation, or recanalization of the embolized artery (19). Furthermore, patients with large HCC can rarely achieve complete remission by TACE alone.

To overcome the limitations associated with TACE, combined treatment with radiation therapy can produce synergistic effects such as the elimination of residual cancer cells following TACE. Tumor shrinkage after TACE allows the use of smaller irradiation fields, which permits higher tumor doses and improves normal liver tolerance. Furthermore, retainment of the anticancer drug in the tumor has been documented to have a radiosensitizing effect (20, 21).

There are few reports that have examined the patients with HCC who underwent hepatectomy following TACE and radiation therapy. The response rates of advanced and unresectable HCC treated with only TACE and radiation therapy were previously reported to be 18-65.8% in the review of the literatures (22-25). The response rate calculated by the proportion of CR and PR according to RECIST criteria based on CT scan was 12.5% (two of sixteen patients). However, actually the pathologic specimen showed CR in 10 patients (total necrosis) and PR in 5 patients (80-95% necrosis). There-

fore reduction of tumor size in imaging study did not reflect the response to treatment exactly.

Fourteen patients showed greater than 90% necrosis. The role of tumor necrosis in patient prognosis remains controversial. Some authors reported that the extent of necrosis was not a favorable prognostic factor (26, 27). Other authors have reported that preoperative TACE resulted in better disease-free survival rates when complete tumor necrosis was induced (28). In our study, the two patients who survived beyond 5 yr showed total tumor necrosis on the specimen. In patients with partial necrosis, the remaining tumor cells are less firmly attached and more likely to be dislodged into the bloodstream during hepatic resection (28, 29). The residual viable cancer cells may facilitate tumor progression and induce intrahepatic metastasis. Such intrahepatic recurrences are considered to arise from intrahepatic metastasis by means of venous dissemination (30). However it is still unclear that tumor necrosis improves the disease-free survival or the pattern of recurrence after curative resection of HCC.

In the 16 patients who underwent hepatectomy following TACE and radiation therapy, tumors recurred in eight cases mostly within 4 months of the operation. The median survival duration was 13.3 months. The results from patients with unresectable or advanced HCC who were treated with TACE and radiation therapy for palliation and not given surgery at other institutions were reviewed due to rarity of hepatic resection after neoadjuvant TACE and radiation therapy. It seemed that the result of our study did not reveal any survival benefit when compared with the results of these studies (24, 31). In the previous study in our institute, the preoperative TACE and non-TACE group undergoing curative resection greater than 5 cm in size did not show significant difference in disease free survival. And the 16 patients in current study did not reveal any disease free survival benefit comparing with these preoperative TACE and non-TACE group in our institute. And the pattern of recurrence between the TACE and non-TACE groups undergoing curative resection did not reveal any difference (27).

The efficacy of hepatectomy following TACE and radiation therapy was difficult to determine because the number of patients in this study was small. In this retrospective study, the prognosis of HCC patients who underwent hepatectomy following TACE and radiation therapy was not satisfactory although two long term survivors were noted. Surgical resection can be one of treatment option when the patient did not show complete response following TACE and radiation therapy. Therefore further research will be required to examine the survival and disease control effect in a prospective randomized study.

REFERENCES

1. Parkin DM, Bray F, Ferlay J, Pisani P. *Estimating the world cancer*

- burden: globocan 2000. *Int J Cancer* 2001; 94: 153-6.
2. Korean statistical information system. Annual report on the cause of death statistics. Available at: <http://kosis.kr>.
 3. Makuuchi M, Takayama T, Kubota K, Kimura W, Midorikawa Y, Miyagawa S, Kawasaki S. Hepatic resection for hepatocellular carcinoma--Japanese experience. *Hepatogastroenterology* 1998; 45: 1267-74.
 4. Tsuzuki T, Sugioka A, Ueda M, Iida S, Kanai T, Yoshii H, Nakayasu K. Hepatic resection for hepatocellular carcinoma. *Surgery* 1990; 107: 511-20.
 5. Kim SS, Lee CD, Choi SW, Han NI, Kim JI, Han SW, Yoon SK, Yang JM, Park YM, Han SW, Lee YS, Park DH, Kim BS. Prognosis and prognostic factors in patients with hepatocellular carcinoma treated by transarterial chemoembolization. *Korean J Gastroenterol* 1997; 30: 72-80.
 6. Uchida M, Kohno H, Kubota H, Hayashi T, Yamanoi A, Kimoto T, Ono T, Nagasue N. Role of preoperative transcatheter arterial oily chemoembolization for resectable hepatocellular carcinoma. *World J Surg* 1996; 20: 326-31.
 7. Majno PE, Adam R, Bismuth H, Castaing D, Ariche A, Krissat J, Perin H, Azoulay D. Influence of preoperative transarterial lipiodol chemoembolization on resection and transplantation for hepatocellular carcinoma in patients with cirrhosis. *Ann Surg* 1997; 226: 688-701.
 8. Sasaki Y, Imaoka S, Kasugai H, Fujita M, Kawamoto S, Ishiquro S, Kojima J, Ishikawa O, Ohigashi H, Furukawa H, Koyama H, Iwanaga T. A new approach to chemoembolization therapy for hepatoma using ethiodized oil, cisplatin, and gelatin sponge. *Cancer* 1987; 60: 1194-203.
 9. Dhir V, Swaroop VS, Mohandas KM, Dinshaw KA, Desai DC, Nagral A, Sharma V, Jagannath P, Desouza LJ. Combination chemotherapy and radiation for palliation of hepatocellular carcinoma. *Am J Clin Oncol* 1992; 15: 304-7.
 10. Epstein B, Ettinger D, Leichner PK, Order SE. Multimodality cisplatin treatment in nonresectable alpha-fetoprotein-positive hepatoma. *Cancer* 1991; 67: 896-900.
 11. Lau WY, Leung TW, Lai BS, Liew CT, Ho SK, Yu SC, Tang AM. Preoperative systemic chemioimmunotherapy and sequential resection for unresectable hepatocellular carcinoma. *Ann Surg* 2001; 233: 236-41.
 12. Ku Y, Iwasaki T, Tominaga M, Fukumoto T, Takahashi T, Kido M, Ogata S, Takahashi M, Kuroda Y, Matsumoto S, Obara H. Reductive surgery plus percutaneous isolated hepatic perfusion for multiple advanced hepatocellular carcinoma. *Ann Surg* 2004; 239: 53-60.
 13. Makuuchi M, Liver Cancer Study Group of Japan: Stage. *The general rules for the clinical and pathological study of primary liver cancer*. 4th Ed. Tokyo: Kanahara and Co; 2000: 19.
 14. Padhani AR, Ollivier L. The RECIST (Response Evaluation Criteria in Solid Tumors) criteria: implications for diagnostic radiologists. *Br J Radiol* 2001; 74: 983-6.
 15. Meric F, Patt YZ, Curley SA, Chase J, Roh MS, Vauthey JN, Ellis LM. Surgery after downstaging of unresectable hepatic tumors with intra-arterial chemotherapy. *Ann Surg Oncol* 2000; 7: 490-5.
 16. Nagasue N, Galizia G, Kohno H, Chang YC, Hayashi T, Yamanoi A, Nakamura T, Yukaya H. Adverse effects of preoperative hepatic artery chemoembolization for resectable hepatocellular carcinoma: a retrospective comparison of 138 liver resections. *Surgery* 1989; 106: 81-6.
 17. Sasaki A, Iwashita Y, Shibata K, Ohta M, Kitano S, Mori M. Preoperative transcatheter arterial chemoembolization reduces long-term survival rate after hepatic resection for resectable hepatocellular carcinoma. *Eur J Surg Oncol* 2006; 32: 773-9.
 18. Lu CD, Peng SY, Jiang XC, Chiba Y, Tanigawa N. Preoperative transcatheter arterial chemoembolization and prognosis of patients with hepatocellular carcinomas: retrospective analysis of 120 cases. *World J Surg* 1999; 23: 293-300.
 19. Gotohda N, Kinoshita T, Konishi M, Nakagohri T, Takahashi S, Furuse J, Ishii H, Yoshino M. New indication for reduction surgery in patients with advanced hepatocellular carcinoma with major vascular involvement. *World J Surg* 2006; 30: 431-8.
 20. Guo WJ, YU EX, Liu LM, Li J, Chen Z, Lin JH, Meng ZQ, Feng Y. Comparison between chemoembolization combined with radiotherapy and chemoembolization alone for large hepatocellular carcinoma. *World J Gastroenterol* 2003; 9: 1697-701.
 21. Seong J, Kim SH, Suh CO. Enhancement of tumor radioresponse by combined chemotherapy in murine hepatocarcinoma. *J Gastroenterol Hepatol* 2001; 16: 883-9.
 22. Seong J, Keum KC, Han KH, Lee DY, Lee JT, Chon CY, Moon YM, Suh CO, Kim GE. Combined transcatheter arterial chemoembolization and local radiotherapy of unresectable hepatocellular carcinoma. *Int J Radiat Oncol Biol Phys* 1999; 43: 393-7.
 23. Shim SJ, Seong J, Han KH, Chon CY, Suh CO, Lee JT. Local radiotherapy as a complement to incomplete transcatheter arterial chemoembolization in locally advanced hepatocellular carcinoma. *Liver Int* 2005; 25: 1189-96.
 24. Zhou ZH, Liu LM, Chen WW, Men ZQ, Lin JH, Chen Z, Zhang XJ, Jiang GL. Combined therapy of transcatheter arterial chemoembolization and three dimensional-dimensional conformal radiotherapy for hepatocellular carcinoma. *Br J Radiol* 2007; 80: 194-201.
 25. Yamada K, Izaki K, Sugimoto K, Mayahara H, Morita Y, Yoden E, Matsumoto S, Soejima T, Sugimura K. Prospective trial of combined transcatheter arterial chemoembolization and three-dimensional conformal radiotherapy for portal vein tumor thrombus in patients with unresectable hepatocellular carcinoma. *Int J radiat Oncol Biol Phys* 2003; 57: 113-9.
 26. Harada T, Matsuo K, Inoue T, Tamesue S, Inoue T, Nakamura H. Is preoperative hepatic arterial chemoembolization safe and effective for hepatocellular carcinoma? *Ann Surg* 1995; 224: 4-9.
 27. Choi GH, Kim DH, Kang CM, Kim KS, Choi JS, Lee WJ, Kim BR. Is preoperative transarterial chemoembolization needed for a resectable hepatocellular carcinoma? *World J Surg* 2007; 31: 2370-7.
 28. Adachi E, Matsumata T, Nishizaki T, Hashimoto H, Tsuneyoshi M, Sugimachi K. Effects of preoperative transcatheter hepatic arterial chemoembolization for hepatocellular carcinoma. The relationship between postoperative course and tumor necrosis. *Cancer* 1993; 72: 3593-8.
 29. Liou TC, Shih SC, Kao CR, Chou SY, Lin SC, Wang HY. Pulmonary metastasis of hepatocellular carcinoma associated with transar-

- terial chemoembolization. J Hepatol 1995; 23: 563-8.*
30. Poon RT, Fan ST, Ng IO, Wong J. *Significance of resection margin in hepatectomy for hepatocellular carcinoma: a critical reappraisal. Ann Surg 2000; 231: 544-51.*
31. Cheng JC, Chuang VP, Cheng SH, Huang AT, Lin YM, Cheng TI,

Yang PS, You DL, Jian JJ, Tsai SY, Sung JL, Horng CF. *Local radiotherapy with or without transcatheter arterial chemoembolization for patients with unresectable hepatocellular carcinoma. Int J Radiat Oncol Biol Phys 2000; 47: 435-42.*