

Clinical Article

Characteristics and Management of Residual or Slowly Recurred Intracranial Aneurysms

Eun-Hyun Ihm, M.D.,¹ Chang-Ki Hong, M.D.,^{1,4} Yu-Shik Shim, M.D.,² Jin-Young Jung, M.D.,^{1,4} Jin-Yang Joo, M.D.,¹ Seoung-Woo Park, M.D.³

Department of Neurosurgery,¹ Gangnam Severance Hospital, Yonsei University College of Medicine, Seoul, Korea

Department of Neurosurgery,² Konkuk University Hospital, Cheongju, Korea

Department of Neurosurgery,³ Kangwon National University Hospital, Gangwon, Korea

Severance Institute of Vascular and Metabolic Research,⁴ Yonsei University College of Medicine, Seoul, Korea

Objective : Residual aneurysm from incomplete clipping or slowly recurrent aneurysm is associated with high risk of subarachnoid hemorrhage. We describe complete treatment of the lesions by surgical clipping or endovascular treatment.

Methods : We analyzed 11 patients of residual or recurrent aneurysms who had undergone surgical clipping from 1998 to 2009. Among them, 5 cases were initially clipped at our hospital. The others were referred from other hospitals after clipping. The radiologic and medical records were retrospectively analyzed.

Results : All patients presented with subarachnoid hemorrhage at first time, and the most frequent location of the ruptured residual or recurrent aneurysm was in the anterior communicating artery to posterior-superior direction. Distal anterior cerebral artery, posterior communicating artery, and middle cerebral artery was followed. Repositioning of clipping in eleven cases, and one endovascular treatment were performed. No residual aneurysm was found in postoperative angiography, and no complication was noted in related to the operations.

Conclusion : These results indicate the importance of postoperative or follow up angiography and that reoperation of residual or slowly recurrent aneurysm should be tried if such lesions being found. Precise evaluation and appropriate planning including endovascular treatment should be performed for complete obliteration of the residual or recurrent aneurysm.

KEY WORDS : Intracranial aneurysm · Subarachnoid hemorrhage · Reoperation.

INTRODUCTION

For many years surgical clipping has been used in treatment of intracranial aneurysms. Development of three dimensional angiography and endovascular technique has contributed to gain better results of aneurysm treatment. Nevertheless, good surgical results are not always achieved and occasionally further evaluation and retreatment might be needed¹¹⁾. Some authors report very small size of residual aneurysm such as dog ear seen in postoperative angiography has less risk of hemorrhage, but subarachnoid hemorrhage (SAH) from a narrow residual neck have reported in many cases. According

to Feurberg et al.¹⁰⁾, incomplete clipping rate vary from 1.6 to 14%^{16,24)}. Recurrent aneurysm developed by arterial wall damage from earlier manipulation and clip edge is different from residual aneurysm in that the former is possible even if complete clipping has performed. But, the prevention and management of hemorrhage is a difficult problem to neurosurgeon.

The purpose of this study was to present the usefulness of postoperative or follow up angiography and management of residual or recurrent intracranial aneurysms based on the authors' experience over the past eleven years.

MATERIALS AND METHODS

Between 1998 and 2009, 857 surgical clipping of intracranial aneurysms were performed at our hospital. This study includes eleven patients with residual or recurrent aneurysms. The patients' age at first surgery ranged from 44 to 70 years (mean 53.90). There were 4 men and 7 women. The mean

• Received : June 13, 2010 • Revised : September 25, 2010

• Accepted : October 5, 2010

• Address for reprints : Chang-Ki Hong, M.D.

Department of Neurosurgery, Gangnam Severance Hospital, Yonsei University College of Medicine, 712 Eonju-ro, Gangnam-gu, Seoul 135-720, Korea

Tel : +82-2-2019-3398, Fax : +82-2-3461-9229

E-mail : yedamin@yuhs.ac

latent period from initial treatment to rupture was about 15.2 days. Whereas recurrent aneurysms were detected with a mean latency of 8.12 years from the initial treatment. The first clinical presentation in all cases was SAH. All 11 cases underwent microsurgical clip as the primary therapy. Among these, six patients who suffered recurrent SAH were referred to our clinic for regrowth of the aneurysmal sac. Three were detected by routine postoperative angiography; the other was found as a consequence of evaluation of other aneurysms (Table 1).

RESULTS

The residual or recurrent aneurysms were diagnosed based on the completeness of initial treatment by angiography and intraoperative findings. We reviewed retrospectively, the patients' intraoperative videos and images to find all cases with the incomplete clipping. Recurrent aneurysms were detected either after several years by angiography when presented SAH or follow up due to another untreated aneurysms.

Residual aneurysms were found in 6 out of 11 patients, recurrent aneurysms were found in 3 patients, and the distinct etiologies could not found in remaining cases.

Residual aneurysms

The most common location of residual aneurysms was in

anterior communicating artery (ACOA). Four aneurysms were located in ACOA, and the others were located in middle cerebral artery, and distal anterior cerebral artery (DACA). All patients presented with SAH due to rupture of residual aneurysm, which were identified on conventional angiography. The mean latent period from initial treatment to rupture was about 15.2 days. The confirmation of residual aneurysm was relatively easy because incomplete clipping with residual neck distal to the clip was verified in both preoperative angiography and intraoperative findings. In one patient (case 4), progressive clip slippage was noted in ACOA aneurysm (Fig. 1). Five patients underwent reoperation with application of a new clip after removal of the former clips. One patient (case 1) was treated by endovascular embolization and good result was achieved (Fig. 2). The outcomes were good for all patients without any complications.

Recurrent aneurysms

The two recurrent aneurysms after initial complete clipping were mostly in posterior communicating arteries. The other two aneurysms were located in ACOA and DACA. The mean latent period from initial treatment to rupture was about 8.12 years. Surgical clipping was performed in the all patients using new clips. The previous clip was kept in one patient (case 7) with the recurrent part being clipped with new clips (Fig. 3). The outcomes were good for all patients

Table 1. Summary of 12 cases of incomplete clipping or regrowing aneurysm

No.	Age/Sex	Location of aneurysm	Size	Initial presentation	Initial treatment	Retreatment	Time interval*	Outcome	Reason for failed treatment
1	49/M	ACOA	Small	SAH	Clipping	Coiling	8 d	Good	Clip slippage
2	49/F	A2-3	Small	SAH	Clipping	Clipping	26 d	Good	Incomplete clipping
3	44/F	ACOA	Small	SAH	Clipping	Clipping	19 d	Good	Incomplete clipping
4	46/M	ACOA	Small	SAH	Clipping	Clipping	8 d	Good	Incomplete clipping
5	58/F	MCBIF	Large	SAH	Clipping	Clipping	18 d	Fair [†]	Incomplete clipping
6	48/M	MCBIF	Small	SAH	Clipping	Clipping	3 m	Good	Unknown
7	58/F	A2-3	Small	SAH	Clipping	Clipping	36 m	Good	Recur
8	56/M	ACOA	Small	SAH	Clipping	Clipping	72 m	Good	Recur
9	62/F	PCoA	Small	SAH	Clipping	Clipping	12 d	Good	Incomplete clipping
10	70/F	PCoA	N/A	SAH	Clipping	Clipping	136 m	Good	Recur
11	53/F	PCoA	N/A	SAH	Clipping	Clipping	240 m	Good	Unknown

*Between initial clipping or coiling and detection of regrowing of aneurysms or residual aneurysms, [†] Due to weakness of right leg after rebleeding. ACOA : anterior communicating artery, MCBIF : middle cerebral artery, PCoA : posterior communicating artery

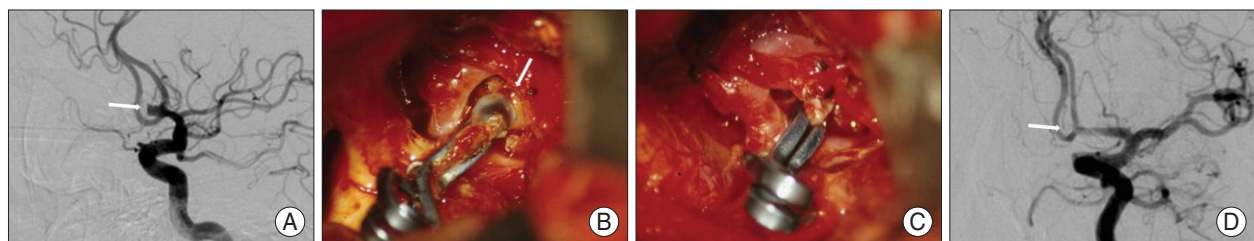


Fig. 1. A : Initial angiogram of a ruptured ACOA aneurysm. B : Intraoperative photograph depicting the residual aneurysm and slipped clip. C : Intraoperative photograph obtained after reposition of clip. D : Postoperative angiogram demonstrating a complete occlusion of aneurysmal remnant.

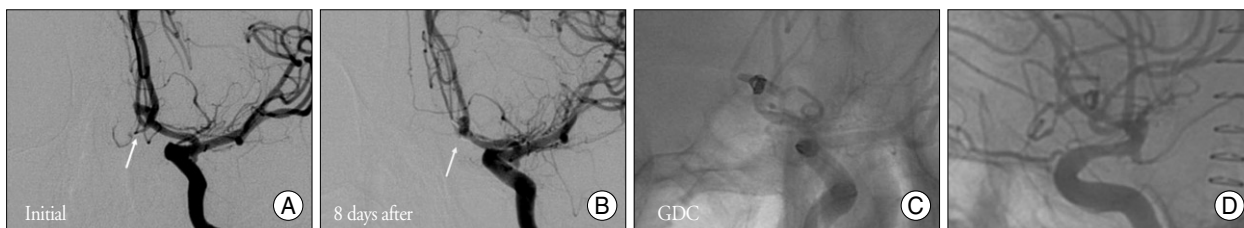


Fig. 2. A : Angiography obtained immediately after SAH, revealing an aneurysm of the ACOA. B : Postoperative angiogram demonstrating a residual, superiorly projecting aneurysm. C and D : Angiogram obtained after complete endovascular occlusion of the aneurysm remnant.

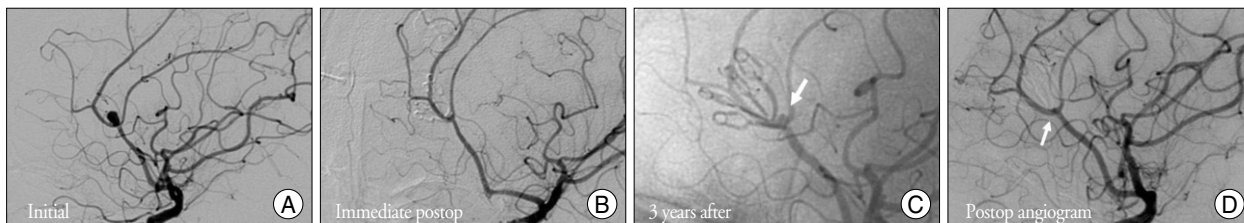


Fig. 3. A : Initial angiography showing the aneurysm on DACA. B : Immediate postoperative angiography demonstrating complete occlusion of the aneurysm. C : Angiogram obtained 3 years after clipping, revealing recurrence of the aneurysm. D : Postoperative angiogram exhibiting complete occlusion of the remnant sac.

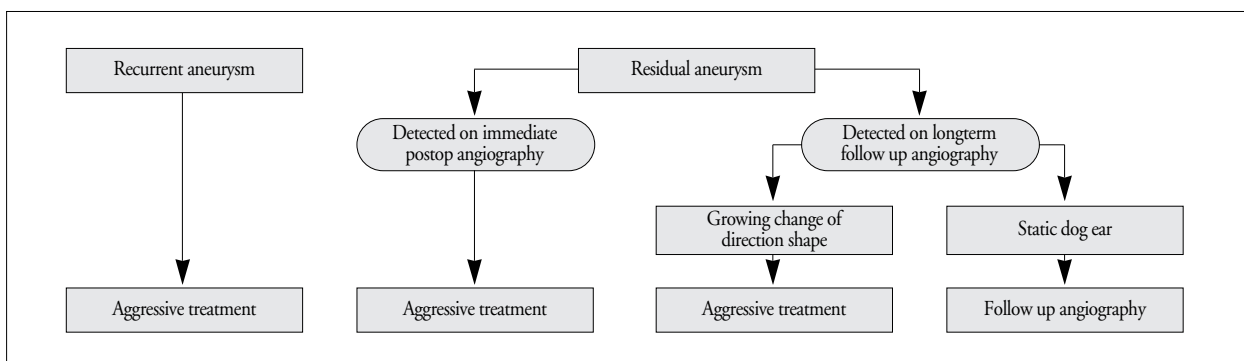


Fig. 4. Management of recurrent or residual aneurysms.

without any complication like residual aneurysm.

DISCUSSION

Delayed detected intracranial aneurysms after initial treatment are classified into two types. One is residual aneurysm arising from initial incomplete treatment, and the other is slowly developed eccentrically in relation to the clip, or existed from a dome between the previous clips²².

Despite small sized residual aneurysms have been thought to pose relatively little risk, incomplete clipping of intracranial aneurysm may result in progressive enlargement of residual portion and rupture of weak point. The rates of residual aneurysm after initial clipping have been reported about 3.8 to 18%^{3,7,8,10,14-16,23}. It can also present with neurologic symptoms from local mass effect^{8,14}. The rebleeding rate of aneurysms with residual necks has been reported to be about 3.5 to 28%^{7,8,10}, and aneurysm regrowth has been reported to occur in 3.5-15% patients^{8,10}. Fuerberg et al.¹⁰, found that residual aneurysms rebled at a rate of about 0.5% per year.

Consequently, treatment of the residual aneurysm is mandatory especially in young age¹⁴.

According to Ebina et al.⁹, recurrent aneurysm can be developed by arterial wall damage from earlier manipulation and applied clip edge. In a completely clipped aneurysm, recurrent hemorrhage and recurrent aneurysm formation are very rare events², and the risk of annual regrowth rate of a completely clipped aneurysm (0.26%) is much lower than the annual risk of *de novo* aneurysm formation (0.89%)²⁵. However, a 2.7% rate of aneurysm rerupture was reported even after complete surgical clipping of the aneurysm⁴. In this regard, a new multidisciplinary decision-making process has been performed⁶.

Cause of residual or recurrent aneurysm

Incomplete clipping occurs as results of inadequate exposure, incomplete dissection, or poor visualization of the aneurysm. Also, other factors such as inappropriate clips or insufficient surgeon's experience can be considered as barrier to the complete clipping. Fragility of the parent artery adjacent to

the aneurysm⁹), vessel injury due to repeated temporary clipping²⁴), and lack of detection also cause incomplete clipping, because postoperative angiography was not routinely performed¹⁶). On the other hand, recurrent aneurysm will slowly progressive, even with complete clipping in the initial treatment due to hemodynamic stress, clip slippage⁷.

Diagnosis of residual or recurrent aneurysm

Residual aneurysm due to incomplete clipping is not detected until a postoperative angiography is performed, except in cases where it is left remain by intention such as risk of obliteration of perforator, or severe atherosclerotic change on aneurysm neck. Postoperative angiography gives some risk and financial burden to the majority of patients whose aneurysms proven to be adequately treated²⁰). Although postoperative angiography is not routinely performed, it should be done whenever incomplete clipping is doubted in operation or in difficult cases. Recently, three dimensional angiography has made diagnosis more accurate^{1,13}).

In diagnosis of recurrent aneurysm, considering that SAH is a catastrophic event, adequate length of follow up ensure the future safety of the patient. In one study, the majority of new aneurysm were found in patients who had undergone angiography more than 9 years after initial treatment. And majority of the these patients developed SAH after 9 years²⁵). Another study reported that average time was 9.75 years for symptoms due to mass effect and 10.5 years for bleeding¹¹). These statistical studies tell us that, considering of the fatality rate of SAH, follow-up investigation may be needed about 10 years after surgery even for patients with completely clipped aneurysms^{11,25,26}). Moreover, in patients who had risk factors more frequent follow-up angiography may be indicated (e.g., 3-5years)^{17,21,25,26}.

Reoperation

Feuerberg et al.¹⁰) reported reoperation is not necessary because the risk of residual aneurysm in some cases is very low. Sato et al.²³) even reported spontaneous obliteration of recurrent aneurysms. In contrast, Drake and Allcock insisted on reoperation to eliminate the risk. Lin et al.¹⁴) suggested that the risk of 1 to 2 mm sized small aneurysm is the same as that for a large residual aneurysm.

Reoperation can be a difficult procedure because of arachnoid adhesion and scar formation. And, because the previous clip is situated in compromising position, removal and repositioning of newly applying clip can be more difficult. Intraoperative rupture or tearing of the parent artery should be managed properly. Some reported that intracerebral hemorrhage can occur more often with a poor outcome^{8,14}). Giannotta and Litofsky¹¹) reported that the removal of the previously

applied clip is always required to completely secure the aneurysm.

A wide exposure and complete dissection of the aneurysm are required. After pertinent bony exposure and slacking down the brain, proximal control for preparing the premature rupture and complete neck dissection should be done. Preparation of adequate clip preparation is also mandatory. The previous applied clip can be a barrier to new clipping. Therefore, if it is possible after securing the parent artery, it may be removed. When it is difficult to secure the parent artery due to severe adhesion, only residual portion can be clipped. Intraoperative angiography can useful help for complete clipping of residual aneurysm³). Because of these difficulties in surgical treatment, endovascular treatment can be a good option. However, it can't be used in a very small residual aneurysms or when a parent vessel cannot be selected or a parent vessel cannot be distinguishable or incorporated from the neck of aneurysms^{5,12,19}).

Management strategy (Fig. 4)

Aggressive treatment must be considered from the fact that residual or recurrent aneurysm may cause fatal SAH. In particular, residual aneurysm from incomplete clipping has quite different characteristics. Postoperative aneurysm neck after incomplete clipping is known to result in recurrent hemorrhage with serious consequences. Most presentations of recurrence reported in the literature were SAH¹⁸). If an aneurysm is detected on postoperative angiography, careful consideration should be given for treatment strategies and follow-up. If an aneurysm has a static dog ear neck, repeated angiography and close observation are necessary. Aggressive treatment is necessary if the aneurysm shape has changed or enlarged (Fig. 4).

Reoperation for residual aneurysm is a difficult approach and requires more meticulous surgical technique than the initial operation. The direct reoperation is often challenging due to scar adhesions to the surrounding tissue as a result of the previous operation. Especially, adhesion is more severe in recurrent aneurysm because time interval from initial treatment to rebleeding is long. Therefore, the surgical anatomy may be obscure and confusing; caution should be exercised during the dissection, and it is preferable to check the initial operation by video or operative records before conducting the second surgery¹⁸). A wide exposure and fine dissection of the aneurysm are also essential. Proximal control for preparing the premature rupture and complete neck dissection should be types of clip should be prepared for proper selection. When clipping, a previous compromisingly positioned clip can interfere with the new clipping. Therefore, if it is possible after securing the parent artery, the old clip should

be removed first and reclipping is favorable for a successful occlusion. But, due to possible severe adhesion and difficulty in securing the parent artery, clipping the residual sac should be very careful. In our series, ten patients (except case 2) were occluded with new clips after removal of previous clip. Therefore, when intraoperative angiogram can be used, the completeness of the clipping of the neck needs to be confirmed during operation³⁾.

If the possibility of recurrence is suspected, additional reinforcement following neck clipping and early postoperative angiography should be performed to prevent early rebleeding²⁷⁾. The endovascular procedure should be considered as an alternative to microsurgical treatment in all patients with residual or recurrent aneurysm, but it can't be used when the aneurysm is tiny.

CONCLUSION

Residual or recurrent aneurysm has high risk of rupture and aggressive treatment is necessary. Postoperative or follow up angiography at least 10 years should be performed in even after complete clipping. When the residual or recurrent aneurysm is found, careful evaluation and appropriate planning are required. Endovascular treatment can be a good alternative treatment.

• Acknowledgements

This study was supported by a faculty research grant of Yonsei University College of Medicine for 6-2007-0039.

References

1. Ahn SS, Kim YD : Three-dimensional digital subtraction angiographic evaluation of aneurysm remnants after clip placement. *J Korean Neurosurg Soc* 47 : 185-190, 2010
2. Asgari S, Wanke I, Schoch B, Stolke D : Recurrent hemorrhage after initially complete occlusion of intracranial aneurysms. *Neurosurg Rev* 26 : 269-274, 2003
3. Barrow DL, Boyer KL, Joseph GJ : Intraoperative angiography in the management of neurovascular disorders. *Neurosurgery* 30 : 153-159, 1992
4. Brilstra EH, Rinkel GJ, van der Graaf Y, van Rooij WJ, Algra A : Treatment of intracranial aneurysms by embolization with coils : a systematic review. *Stroke* 30 : 470-476, 1999
5. Byrne JV, Molyneux AJ, Brennan RP, Renowden SA : Embolisation of recently ruptured intracranial aneurysms. *J Neurol Neurosurg Psychiatry* 59 : 616-620, 1995
6. Conrad MD, Pelissou-Guyotat I, Morel C, Madarassy G, Schonauer C, Deruty R : Regrowth of residual ruptured aneurysms treated by Guglielmi's Detachable Coils which demanded further treatment by surgical clipping : report of 7 cases and review of the literature. *Acta Neurochir (Wien)* 144 : 419-426, 2002
7. Drake CG, Allcock JM : Postoperative angiography and the "slipped" Clip. *J Neurosurg* 39 : 683-689, 1973

8. Drake CG, Friedman AH, Peerless SJ : Failed aneurysm surgery. Reoperation in 115 cases. *J Neurosurg* 61 : 848-856, 1984
9. Ebina K, Suzuki M, Andoh A, Saitoh K, Iwabuchi T : Recurrence of cerebral aneurysm after initial neck clipping. *Neurosurgery* 11 : 764-768, 1982
10. Feuerberg I, Lindquist C, Lindqvist M, Steiner L : Natural history of postoperative aneurysm rests. *J Neurosurg* 66 : 30-34, 1987
11. Giannotta SL, Litofsky NS : Reoperative management of intracranial aneurysms. *J Neurosurg* 83 : 387-393, 1995
12. Hoh BL, Carter BS, Putman CM, Ogilvy CS : Important factors for a combined neurovascular team to consider in selecting a treatment modality for patients with previously clipped residual and recurrent intracranial aneurysms. *Neurosurgery* 52 : 732-738; discussion 738-739, 2003
13. Kang HS, Han MH, Kwon BJ, Jung SI, Oh CW, Han DH, et al. : Postoperative 3D angiography in intracranial aneurysms. *AJNR Am J Neuroradiol* 25 : 1463-1469, 2004
14. Lin T, Fox AJ, Drake CG : Regrowth of aneurysm sacs from residual neck following aneurysm clipping. *J Neurosurg* 70 : 556-560, 1989
15. Lot G, Houdart E, Cophignon J, Casasco A, George B : Combined management of intracranial aneurysms by surgical and endovascular treatment. Modalities and results from a series of 395 cases. *Acta Neurochir (Wien)* 141 : 557-562, 1999
16. Macdonald RL, Wallace MC, Kestle JR : Role of angiography following aneurysm surgery. *J Neurosurg* 79 : 826-832, 1993
17. Miller CA, Hill SA, Hunt WE : "De novo" Aneurysms. A clinical review. *Surg Neurol* 24 : 173-180, 1985
18. Nakase H, Kamada Y, Aoki H, Goda K, Morimoto T, Sakaki T : Clinical study on recurrent intracranial aneurysms. *Cerebrovasc Dis* 10 : 255-260, 2000
19. Raja PV, Huang J, Germanwala AV, Gaillood P, Murphy KP, Tamargo RJ : Microsurgical clipping and endovascular coiling of intracranial aneurysms : a critical review of the literature. *Neurosurgery* 62 : 1187-1202; discussion 1202-1203, 2008
20. Rauzzino MJ, Quinn CM, Fisher WS 3rd : Angiography after aneurysm surgery : indications for "selective" angiography. *Surg Neurol* 49 : 32-40; discussion 40-41, 1998
21. Rinne JK, Hernesniemi JA : De novo aneurysms : Special multiple intracranial aneurysms. *Neurosurgery* 33 : 981-985, 1993
22. Sakaki T, Takeshima T, Tominaga M, Hashimoto H, Kawaguchi S : Recurrence of ICA-PCoA aneurysms after neck clipping. *J Neurosurg* 80 : 58-63, 1994
23. Sato S, Suzuki J : Prognosis in cases of intracranial aneurysm after incomplete direct operations. *Acta Neurochir (Wien)* 24 : 245-252, 1971
24. Sindou M, Acevedo JC, Turjman F : Aneurysmal remnants after microsurgical clipping : classification and results from a prospective angiographic study (in a consecutive series of 305 operated intracranial aneurysms). *Acta Neurochir (Wien)* 140 : 1153-1159, 1998
25. Tsutsumi K, Ueki K, Morita A, Usui M, Kirino T : Risk of aneurysm recurrence in patients with clipped cerebral aneurysms : results of long-term follow-up angiography. *Stroke* 32 : 1191-1194, 2001
26. Tsutsumi K, Ueki K, Usui M, Kwak S, Kirino T : Risk of recurrent subarachnoid hemorrhage after complete obliteration of cerebral aneurysms. *Stroke* 29 : 2511-2513, 1998
27. Yamakawa H, Sakai N, Takenaka K, Yoshimura S, Andoh T, Yamada H, et al. : Clinical analysis of recurrent subarachnoid hemorrhage after neck clipping surgery. *Neurol Med Chir (Tokyo)* 37 : 380-385; discussion 385-386, 1997