

# Sympathetic Nerve Reconstruction for Compensatory Hyperhidrosis after Sympathetic Surgery for Primary Hyperhidrosis

We performed sympathetic nerve reconstruction using intercostal nerve in patients with severe compensatory hyperhidrosis after sympathetic surgery for primary hyperhidrosis, and analyzed the surgical results. From February 2004 to August 2007, sympathetic nerve reconstruction using intercostal nerve was performed in 19 patients. The subjected patients presented severe compensatory hyperhidrosis after thoracoscopic sympathetic surgery for primary hyperhidrosis. Reconstruction of sympathetic nerve was performed by thoracoscopic surgery except in 1 patient with severe pleural adhesion. The median interval between the initial sympathetic surgery and sympathetic nerve reconstruction was 47.2 (range: 3.5-110.7) months. Compensatory sweating after the reconstruction surgery improved in 9 patients, and 3 out of them had markedly improved symptoms. Sympathetic nerve reconstruction using intercostal nerve may be one of the useful surgical options for severe compensatory hyperhidrosis following sympathetic surgery for primary hyperhidrosis.

**Key Words :** *Hyperhidrosis; Nerve Transfer; Sympathetic Nerve; Thoracoscopy*

© 2010 The Korean Academy of Medical Sciences.

This is an Open Access article distributed under the terms of the Creative Commons Attribution Non-Commercial License (<http://creativecommons.org/licenses/by-nc/3.0>) which permits unrestricted non-commercial use, distribution, and reproduction in any medium, provided the original work is properly cited.

**Seok Jin Haam, Seung Yong Park,  
Hyo Chae Paik, and Doo Yun Lee**

Department of Thoracic and Cardiovascular Surgery,  
Gangnam Severance Hospital, Yonsei University,  
College of Medicine, Seoul, Korea

Received : 7 March 2009  
Accepted : 21 July 2009

## Address for Correspondence

Doo Yun Lee, M.D.  
Department of Thoracic and Cardiovascular Surgery,  
Gangnam Severance Hospital, Yonsei University,  
College of Medicine, 612 Eonju-ro, Gangnam-gu,  
Seou 135-720, Korea  
Tel : +82.2-2019-3380, Fax : +82.2-3461-8282  
E-mail : dylee@yuhs.ac

## INTRODUCTION

Primary hyperhidrosis is a common disease that is characterized by excessive sweating of face, palms, or axilla, occurring in 0.6-3% of a population (1, 2). Since Kux performed endoscopic thoracic sympathetic surgery (3), it has been popular during the past few decades as the surgical treatment of choice for facial, palmar, and axillary hyperhidrosis (4-6). Although endoscopic thoracic sympathetic surgery offers permanent cure for hyperhidrosis, it is often accompanied by serious complications, such as compensatory hyperhidrosis. In order to decrease compensatory hyperhidrosis, endoscopic thoracic sympathetic surgery has attempted to reduce the extent of resection of the sympathetic nerve, but these procedures did not significantly decrease the occurrence of compensatory hyperhidrosis (7). We performed sympathetic nerve reconstruction surgery using intercostal nerve in 19 patients with severe compensatory hyperhidrosis after endoscopic thoracic sympathetic surgery and evaluated the results of the procedure.

## MATERIALS AND METHODS

From February 2004 to August 2007, we performed endo-

scopic thoracic sympathetic surgery in 184 patients with primary hyperhidrosis. Among these patients, reconstruction surgery of sympathetic nerve using intercostal nerve was performed in 19 patients with severe compensatory hyperhidrosis after endoscopic thoracic sympathetic surgery. Fourteen patients were male and 5 were female (median age: 28 yr, range: 19-61). Two patients were lost during the follow-up period. This study was approved by the Institutional Review Board of our hospital (IRB No: 3-20080021).

All procedures of reconstruction surgery were performed under general anesthesia with a single lumen endotracheal tube. The patients were in a semi-Fowler position with their arms extended. In 18 patients except for one patient with severe pleural adhesion, thoracoscopic surgery was possible. Starting on the left side, two separate skin incisions were made along the previous thoracoscopic scars and thoracoscopic ports were placed. After CO<sub>2</sub> gas insufflation into the thoracic cavity with less than 10 mmHg of pressure to deflate the lung, the pleural space was inspected with 5-mm thoracoscope. Most patients had minimal pleural adhesion around the previous sympathetic surgery site. The intercostal neurovascular bundle was dissected in lengths of 5-7 cm and the distal part was resected. After the proximal and distal part of previously operated sympathetic nerve was exposed, the nerve

sheaths of proximal and distal part of exposed sympathetic nerve and harvested intercostal nerve end were removed with an electro-surgical tip cleaner (Surgisite®, Ethicon, Gargrave, Skipton, UK). The intercostal nerve end was placed between the proximal and distal part of the exposed sympathetic nerve and the fibrin glue was applied to contact surface of the sympathetic and intercostal nerve (Fig. 1). The same procedure was repeated on the right side. In cases of sympathetic nerve clipping, this procedure was performed after clip removal. In one patient with severe pleural adhesion, sympathetic reconstruction was performed by minithoracotomy. All patients were discharged without surgical complications.

We reviewed the clinical charts of all patients who underwent sympathetic nerve reconstruction surgery using the inter-

costal nerve. Patients were followed by telephone questionnaire on the effects of the surgery and postoperative complications. The degree of improvement of compensatory hyperhidrosis was graded as “Definite”, “Mild”, or “Absent”. “Definite” means that patients felt fully satisfied after the reconstruction surgery, “Mild” means that patients felt satisfied to a certain extent, and “Absent” means that patients felt no improvement. Median interval between the sympathetic nerve reconstruction surgery and questionnaire was 22 (range: 1–45) months.

In one patient (patient number 17 in Table 1), digital infrared thermographic imaging was performed preoperatively and postoperatively.

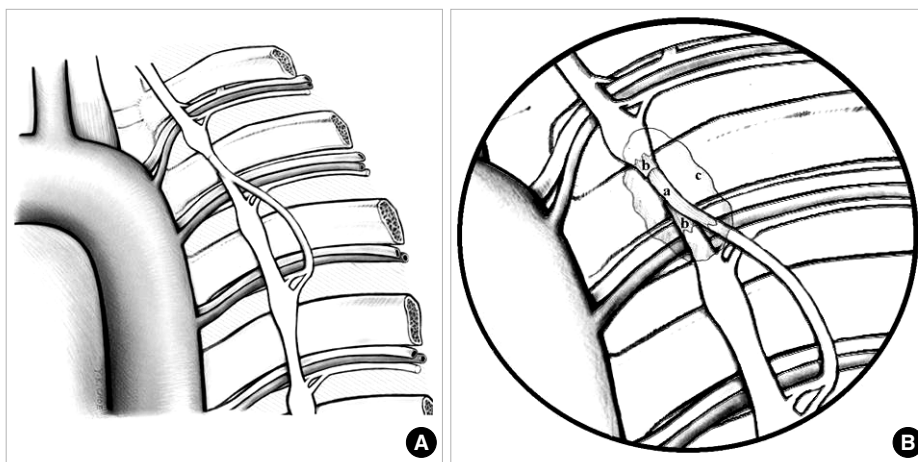


Fig. 1. (A) Illustration of operative field. (B) Magnified view of nerve anastomosis. The distal part of the intercostal nerve (a) was placed between the proximal and distal ends of the exposed sympathetic nerve (b) to contact with the sympathetic nerve and intercostal nerve, and fibrin sealant (c) was applied to the contact surface of the sympathetic and intercostal nerve.

Table 1. Patients' Characteristics and Surgical Results<sup>†‡</sup>

Patient number	Sex	Age (yr)	Site of PHH	Surgery for PHH	Area of CH	Interval* (months)	Surgery for CH	Interval <sup>†</sup> (months)	Effect of SNR
1	M	61	Palm	T3 sympathectomy	Chest, back	44	R4 ICN	45	Absent
2	F	19	Palm	T3 sympathectomy	Chest, back	17	R3 ICN	38	Absent
3	M	21	Face	T2 sympathectomy	Chest, back	12	R3 ICN	-	Loss
4	F	54	Face	T2 sympathectomy	Back, axilla	72	R3 ICN	28	Absent
5	M	20	Palm	T3 sympathectomy	Back, abdomen, thigh	47	R3 ICN	28	Absent
6	M	47	Palm	T2 sympathectomy	Back, abdomen	48	R3 ICN	19	Absent
7	M	28	Face	T2 sympathectomy	Chest	61	R3 ICN	26	Absent
8	F	48	Face	T2 sympathectomy	Chest, back, axilla	36	R3 ICN	26	Definite
9	F	45	Face	T2 clip & T3 sympathectomy	Chest, back	4	R2 ICN	26	Definite
10	M	25	Face, palm	T2, 3 sympathectomy	Chest	60	R3 ICN	-	Loss
11	M	29	Face	T2 clip	Chest, back	54	R3 ICN	22	Absent
12	M	46	Face	T2 clip	Back, abdomen	81	R3 ICN	31	Mild
13	M	23	Axilla	T2 sympathectomy	Whole body	37	R3 ICN	16	Mild
14 <sup>‡</sup>	M	51	Face	T2,3 clip	Chest, abdomen, thigh	12	R3 ICN	16	Mild
15	M	22	Palm	T3 sympathectomy	Chest, abdomen	63	R4 ICN	4	Mild
16	M	35	Face	T2 sympathectomy	Back, thigh, axilla	111	R3 ICN	5	Mild
17	M	22	Palm	T3 sympathectomy	Chest	4	R3 ICN	7	Definite
18	M	28	Palm	T2, 3, 4 sympathectomy	Chest, back, thigh	102	R3,5 ICN	2	Mild
19	F	53	Palm	T2 sympathectomy	Chest, abdomen	43	R3 ICN	1	Absent

\*Interval between sympathetic surgery for primary hyperhidrosis and sympathetic nerve reconstruction surgery; Interval<sup>†</sup>, Interval between sympathetic nerve reconstruction surgery and questionnaire; <sup>‡</sup>Sympathetic nerve reconstruction surgery under thoracotomy.

PHH, primary hyperhidrosis; CH, compensatory hyperhidrosis; SNR, sympathetic nerve reconstruction; ICN, intercostal nerve.

**RESULTS**

Primary hyperhidrosis patients were composed of 9 facial, 8 palmar, and 1 axillary, and one patient had both facial and palmar hyperhidrosis. Table 1 shows the patients' characteristics and results of sympathetic nerve reconstruction surgery. Initial endoscopic thoracic sympathetic surgery for primary hyperhidrosis was T3 sympathicotomy in 5 patients; T2 sympathicotomy in 8; T2, 3 sympathicotomy in 1; T2, 3, 4 sympathicotomy in 1; T2 clipping in 2; T2, 3 clipping in 1; and T2 clipping with T3 sympathicotomy in 1 patient. All patients were operated by thoracoscopic approach.

The chest and back were the most common sites of compensatory hyperhidrosis. The median interval between the first endoscopic thoracic sympathetic surgery for primary hyperhidrosis and sympathetic nerve reconstruction surgery was 47 (range, 4-111) months. R3 intercostal nerve was used for sympathetic nerve reconstruction surgery in 15 patients, R4 intercostal nerve in 2, R2 intercostal nerve in 1, and R3 with R5 intercostal nerve in 1 patient.

Three patients replied that the effects of reconstruction were "Definite", 6 responded with "Mild", and 8 said "Absent". Postoperative complications were numbness of the chest wall in 2 patients, chest wall pain in 2 patients, and temporary ptosis in 1 patient in whom ptosis spontaneously resolved after 3 months.

Preoperative and postoperative digital infrared thermographic imagings performed in one patient showed the thermal change in chest and back. The postoperative trunk temperature was higher than preoperative temperature (Fig. 2).

**DISCUSSION**

Since Kux advocated thoracoscopic sympathetic surgery (3), recent developments in thoracoscopy and specialized instruments have facilitated the procedure. And, it became the treatment of choice for hyperhidrosis because of its low morbidity, short hospital stay, and excellent cosmetic results (6). Although it has many advantages, some patients suffer from compensatory hyperhidrosis, which is by far the most common and disagreeable complication after endoscopic thoracic sympathetic surgery. According to the previous reports, compensatory hyperhidrosis occurs in 59.8-90% of patients after sympathetic surgery (8-10). The mechanism of compensatory hyperhidrosis is not clear, but it seems to be associated with compensation for thermoregulatory function (11, 12). Because the incidence and degree of compensatory hyperhidrosis appear to be related to the extent of resection of the sympathetic chain, some clinicians have suggested that the extent of resection should be limited (13). For these reasons, many treatment methods, such as different level sympathectomy or sympathicotomy, ramicotomy, and clipping, have been attempted to reduce the extent of resection (14-18), although the effects of these methods remain controversial. In mild compensatory symptoms, antiperspirants including aluminum-based compounds, iontophoresis, and systemic or topical anticholinergic drugs can be used. However, if the symptoms are severe, the management is more difficult and results are unsatisfactory.

Since Philipeaux and Vulpian reported the first experimental nerve graft in 1870, many successful nerve grafts were reported in the field of orthopedic surgery. In the field of thoracic surgery, Schoeller et al. (19) reported successful phrenic nerve reconstruction using sural nerve in patient with mediastinal tumor resection. Telaranta reported that reconstruc-

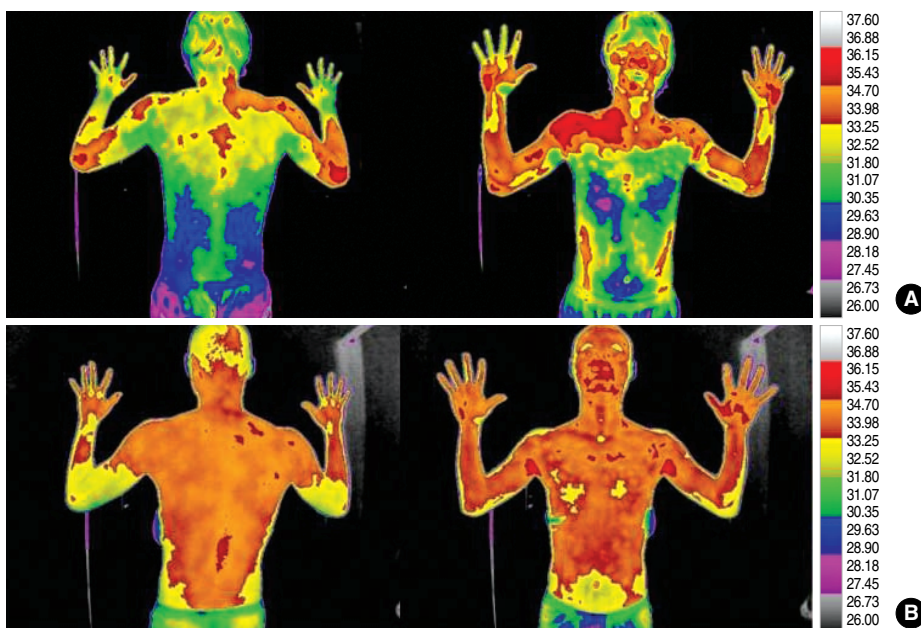


Fig. 2. (A) and (B) are infrared thermographic image obtained before sympathetic reconstruction surgery and after postoperative 3 months, respectively. Preoperative and postoperative digital infrared thermographic imaging show the apparent thermal change in chest and back.

tion of the sympathetic chain using sural nerve graft diminished compensatory sweating in a male patient who underwent sympathicotomy for palmar hyperhidrosis (20). Miura et al. (21) reported that sympathetic nerve reconstruction surgery using the intercostal nerve was useful after resection of the sympathetic nerve involved by tumor.

Although the sural nerve is the most commonly used for nerve graft, the intercostal nerve has several advantages over the sural nerve. First, the intercostal nerve has more sympathetic nerve fibers than the sural nerve, hence the intercostal nerve is more appropriate for sympathetic nerve reconstruction surgery. Second, the sural nerve can be used only as free graft but the intercostal nerve can be used as pedicled graft and harvested as a neurovascular bundle. Therefore, a sufficient blood supply in the graft can be maintained. Third, the intercostal nerve can be harvested by thoracoscopy. So, an additional incision is not needed and donor site morbidity decreases. In our experience, thoracoscopic intercostal nerve could be harvested in all patients except 1 patient with severe pleural adhesion, leading us to believe that the intercostal nerve is a useful graft for sympathetic nerve reconstruction surgery.

Epineural and fascicular sutures are the most used for nerve anastomosis, but the foreign body reaction caused by suture material to nerve is another possible problem (22, 23). Some reports demonstrated the successful nerve anastomosis using fibrin sealant without suture technique (24, 25). If microscopic suture technique is used in sympathetic nerve reconstruction surgery, it inevitably needs thoracotomy. So, we used fibrin sealant for nerve anastomosis. The type of anastomosis performed in this procedure is the modification of end-to-side neurorrhaphy where axonal sprouting occurs (26).

The nerve is generally anastomosed in the original direction, but the free graft should be prepared to be anastomosed in the original direction in this operation. Some reports revealed the anastomosis in reverse orientation did not influence the nerve conduction (27, 28).

In the questionnaire on the effects of sympathetic nerve reconstruction surgery, nine patients replied "Definite" or "Mild". In 3 patients who replied that the results were "Definite", compensatory sweating decreased and anhidrosis of the affected areas after endoscopic thoracic sympathetic surgery improved. Patients, who replied mild improvement, complained still uncomfortable compensatory hyperhidrosis, although amount and frequency of perspiration decreased. However, in 8 patients, sympathetic reconstruction surgery did not show any effect. These results of the reconstruction surgery were not different between variables such as age, sex, affected area, and interval from endoscopic thoracic sympathetic surgery due to the small number of cases in this study.

The digital infrared thermographic imaging is a useful tool in evaluation of body temperature distribution. In the image, sweating area shows lower temperature than other area. Before and after sympathetic nerve reconstruction, we performed the digital infrared thermographic imagings in 22 yr-old man

complaining of compensatory hyperhidrosis in chest after T3 sympathicotomy. After the reconstruction surgery, trunk temperature has increased, and this result corresponded with patient's symptom.

Even though the number of patients is not sufficient for data analysis, outcome of the reconstruction surgery did not correlate with the interval between the sympathetic surgery and reconstructive surgery. To evaluate the exact effects of sympathetic nerve reconstruction, more cases and longer postoperative follow-up period is necessary.

Postoperative complications of the reconstruction surgery were seen in 5 patients; prolonged chest wall pain which was tolerable in 2 patients, and numbness of chest wall in 2 patients. One patient complained of ptosis which was spontaneously resolved after 3 months.

The questionnaire has been used to evaluate the surgical outcome after sympathetic surgery. However, the questionnaire has a limitation that it is not objective. In addition, because compensatory hyperhidrosis depends on climate and season, the timing of a questionnaire survey is important. In this study, the questionnaire was performed on October when it is relatively cool and dry in Korea. This is another limitation in this study.

In conclusion, our results suggest that sympathetic nerve reconstruction with intercostal nerve may be one of the useful surgical methods in severe compensatory hyperhidrosis patients. A half of the patients satisfied with the results. The reconstruction surgery must be decided very carefully in highly selected patients with severe compensatory hyperhidrosis.

## ACKNOWLEDGEMENTS

The authors would like to acknowledge Dr. YK Choe, a medical illustrator for preparing the illustrations.

## REFERENCES

1. Adar R, Kurchin A, Zweig A, Mozes M. *Palmar hyperhidrosis and its surgical treatment: a report of 100 cases. Ann Surg* 1977; 186: 34-41.
2. Lin TS, Fang HY. *Transthoracic endoscopic sympathectomy in the treatment of palmar hyperhidrosis with emphasis on perioperative management (1,360 case analyses). Surg Neurol* 1999; 52: 453-7.
3. Kux EF. *Endoscopic resection of the autonomic nervous system of the thoracic cavity. Rev Esp Tuberc* 1951; 20: 19-24.
4. Shachor D, Jedeikin R, Olsfanger D, Bendahan J, Sivak G, Freund U. *Endoscopic transthoracic sympathectomy in the treatment of primary hyperhidrosis. A review of 290 sympathectomies. Arch Surg* 1994; 129: 241-4.
5. Fox AD, Hands L, Collin J. *The results of thoracoscopic sympathetic trunk transection for palmar hyperhidrosis and sympathetic ganglionectomy for axillary hyperhidrosis. Eur J Vasc Endovasc Surg*

- 1999; 17: 343-6.
6. Drott C, Gothberg G, Claes G. *Endoscopic transthoracic sympathectomy: an efficient and safe method for the treatment of hyperhidrosis.* *J Am Acad Dermatol* 1995; 33: 78-81.
  7. Lee DY, Yoon YH, Shin HK, Kim HK, Hong YJ. *Needle thoracic sympathectomy for essential hyperhidrosis: intermediate-term follow-up.* *Ann Thorac Surg* 2000; 69: 251-3.
  8. Fredman B, Zohar E, Shachor D, Bendahan J, Jedeikin R. *Video-assisted transthoracic sympathectomy in the treatment of primary hyperhidrosis: friend or foe?* *Surg Laparosc Endosc Percutan Tech* 2000; 10: 226-9.
  9. Lin TS, Wang NP, Huang LC. *Pitfalls and complication avoidance associated with transthoracic endoscopic sympathectomy for primary hyperhidrosis (analysis of 2200 cases).* *Int J Surg Investig* 2001; 2: 377-85.
  10. Gossot D, Galetta D, Pascal A, Debrosse D, Caliandro R, Girard P, Stern JB, Grunenwald D. *Long-term results of endoscopic thoracic sympathectomy for upper limb hyperhidrosis.* *Ann Thorac Surg* 2003; 75: 1075-9.
  11. Adar R. *Compensatory sweating after upper dorsal sympathectomy.* *J Neurosurg* 1979; 51: 424-5.
  12. Shih GJ. *Compensatory sweating after upper dorsal sympathectomy.* *J Neurosurg* 1979; 51: 425.
  13. Kao MC. *Video endoscopic sympathectomy using a fiberoptic CO<sub>2</sub> laser to treat palmar hyperhidrosis.* *Neurosurgery* 1992; 30: 131-5.
  14. Gossot D, Toledo L, Fritsch S, Celerier M. *Thoracoscopic sympathectomy for upper limb hyperhidrosis: looking for the right operation.* *Ann Thorac Surg* 1997; 64: 975-8.
  15. Noppen M, Herregodts P, D'Haese J, D'Haens J, Vincken W. *A simplified T2-T3 thoracoscopic sympathicotomy technique for the treatment of essential hyperhidrosis: short-term results in 100 patients.* *J Laparoendosc Surg* 1996; 6: 151-9.
  16. Bonjer HJ, Hamming JF, du Bois N, van Urk H. *Advantages of limited thoracoscopic sympathectomy.* *Surg Endosc* 1996; 10: 721-3.
  17. Drott C, Claes G. *Hyperhidrosis treated by thoracoscopic sympathectomy.* *Cardiovasc Surg* 1996; 4: 788-91.
  18. Chou SH, Kao EL, Lin CC, Chang YT, Huang MF. *The importance of classification in sympathetic surgery and a proposed mechanism for compensatory hyperhidrosis: experience with 464 cases.* *Surg Endosc* 2006; 20: 1749-53.
  19. Schoeller T, Ohlbauer M, Wechselberger G, Piza-Katzer H, Margreiter R. *Successful immediate phrenic nerve reconstruction during mediastinal tumor resection.* *J Thorac Cardiovasc Surg* 2001; 122: 1235-7.
  20. Telaranta T. *Secondary sympathetic chain reconstruction after endoscopic thoracic sympathectomy.* *Eur J Surg Suppl* 1998; 580: 17-8.
  21. Miura J, Doita M, Miyata K, Yoshiya S, Kurosaka M, Yamamoto H. *Horner's syndrome caused by a thoracic dumbbell-shaped schwannoma: sympathetic chain reconstruction after a one-stage removal of the tumor.* *Spine* 2003; 28: E33-6.
  22. Terris DJ, Fee WE Jr. *Current issues in nerve repair.* *Arch Otolaryngol Head Neck Surg* 1993; 119: 725-31.
  23. Parker G, White T, Jenkins R. *Surgical repair of extratemporal facial nerve: a comparison of suture repair and microfibrillar collagen repair.* *Laryngoscope* 1984; 94: 950-3.
  24. Gosk J, Knakiewicz M, Wiacek R, Reichert P. *The use of the fibrin glue in the peripheral nerves reconstructions.* *Polim Med* 2006; 36: 11-5.
  25. Suri A, Mehta VS, Sarkar C. *Microneural anastomosis with fibrin glue: an experimental study.* *Neurol India* 2002; 50: 23-6.
  26. Beris A, Lykissas M, Korompilias A, Mitsionis G. *End-to-side nerve repair in peripheral nerve injury.* *J Neurotrauma* 2007; 24: 909-16.
  27. Sotereanos DG, Seaber AV, Urbaniak JR, Spiegel DA, Sotereanos D, Anthony DC. *Reversing nerve-graft polarity in a rat model: the effect on function.* *J Reconstr Microsurg* 1992; 8: 303-7.
  28. Stromberg BV, Vlastou C, Earle AS. *Effect of nerve graft polarity on nerve regeneration and function.* *J Hand Surg* 1979; 4: 444-5.