

Case report - Thoracic oncologic Treatment of locally advanced thyroid cancer invading the great vessels using a Y-shaped graft bypass

Yong Sang Lee, Woong Youn Chung, Hang-Seok Chang*, Cheong Soo Park

Department of Surgery, Thyroid Cancer Center, Gangnam Severance Hospital, Yonsei University College of Medicine, 712 Eonjuro, Gangnam-gu, 135-720 Seoul, South Korea

Received 20 November 2009; received in revised form 16 February 2010; accepted 3 March 2010

Abstract

Although the presence of aggressive angioinvasion is not a contraindication for surgical treatment of well-differentiated thyroid cancer, surgical resection and reconstruction of the major arteries in the neck and mediastinum using a synthetic graft is rarely performed. We present our experience of resection and reconstruction of the major arteries in the neck for the treatment of locally advanced thyroid cancer. A 66-year-old woman presented with locally advanced thyroid cancer with invasion of the right internal jugular vein and vagus nerve. The cancer mass encased the junction of the right common carotid artery, the subclavian artery, and the brachiocephalic trunk. After en-bloc resection of the tumor, the arteries were reconstructed using a Y-shaped synthetic graft between the common carotid artery, aorta, and the subclavian artery. Postoperatively, there was no evidence of cerebral ischemia and the patient made a rapid recovery without complications. An aggressive surgical approach is appropriate for grossly invasive thyroid cancer to decrease the risk of local recurrence and increase survival. Surgical resection and reconstruction of the major arteries in the neck and chest using a synthetic graft can be an acceptable therapeutic option for locally advanced thyroid cancer.

© 2010 Published by European Association for Cardio-Thoracic Surgery. All rights reserved.

Keywords: Angioinvasion; Locally advanced thyroid cancer; Graft bypass

1. Introduction

Although aggressive invasion of the great vessels by well-differentiated thyroid cancers is not common, the prognosis of patients with such an invasion is very poor [1, 2].

Reduction of the tumor burden generally provides the best chance of a cure for well-differentiated thyroid cancer, and outcomes are usually favorable. As such, the presence of a massive intravascular invasion is not a contraindication for surgical resection even for locally advanced thyroid cancers invading vital organs in the neck and chest [3].

While several cases of resection and reconstruction of the major veins of the neck have been reported [3–6], surgical resection and reconstruction of the major arteries is rarely performed [7, 8].

The present report describes a case of successful surgical treatment of a locally advanced thyroid cancer using resection and reconstruction of the major arteries in the neck and mediastinum. Written informed consent was obtained from the patient for publication.

2. Case description

A 66-year-old woman presented with progressive difficulty in swallowing for the previous four years. The patient had

undergone a right lobectomy of the thyroid gland 30 years before due to a benign thyroid tumor.

Ultrasonography, computed tomography (CT), and magnetic resonance imaging (MRI) revealed thyroid cancer in the thyroid bed invading the right internal jugular vein and nerves, including encasement of the right common carotid artery and brachiocephalic trunk (Fig. 1). Multiple metastatic lymph nodes were observed on the right internal jugular chain and mediastinum. Fine-needle aspiration cytology confirmed papillary thyroid carcinomas with lymph node metastasis.

The operation was performed with therapeutic intent. The patient was placed in the supine position with the neck hyper-extended. A skin incision was made 3 cm superior to the sternal notch with extension laterally to the lateral neck, and a T-shaped incision for a full midline sternotomy was added.

Operative findings showed that the cancer was located in the thyroid bed, and that there was invasion of the trachea, esophagus, right recurrent laryngeal nerve, vagus nerve, and bifurcation of the right brachiocephalic artery. Multiple metastatic nodes were found in the central compartment, right internal jugular node chain, and mediastinum.

Completion thyroidectomy and en-bloc resection of the tumor were performed. Whereas the veins and nerves were sacrificed, the arteries were reconstructed using a Y-shaped synthetic graft [polytetrafluoroethylene (PTFE)] between common carotid artery, aorta, and subclavian artery.

*Corresponding author. Tel.: +82-2-2019-3370; fax: +82-2-3462-5994.
E-mail address: surghsc@yuhs.ac (H.-S. Chang).

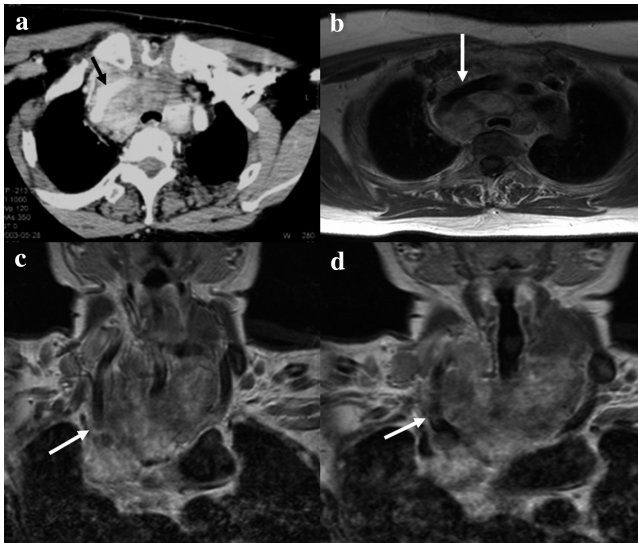


Fig. 1. Preoperative computed tomography (a) and magnetic resonance imaging (b–d) showed the tumor encasement of great vessels of the neck including right common carotid artery (c, d) and brachiocephalic trunk (a, b).

After systemic heparinization, the right common carotid artery was clamped at the midpoint. Before clamping of the common carotid artery, patent back-flow from the common carotid artery was confirmed. The right subclavian artery and the proximal portion of the brachiocephalic trunk were clamped at a distance of 2 cm from the tumor margin (Fig. 2a), and the proximal stump at the aortic origin was closed.

Prior to clamping the vessels, a Y-shaped end-to-side anastomosis was made with 12-mm PTFE grafts using 6.0 Prolene (Fig. 2b). Reconstruction of the arteries was performed with the previously made Y-shaped PTFE graft using 6.0 Prolene (Fig. 2c). Because the subclavian artery was resected at its origin from the aorta, the graft was anastomosed at the newly made opening in the aorta for flow reconstruction. The right common carotid artery was reconstructed prior to the right subclavian artery to minimize ischemic brain damage.

After terminating the anastomosis between the Y-shaped graft and the subclavian artery, any air or debris within the lumen was evacuated via the unattached end of the PTFE graft. After flushing, the suture line was tied and the clamps were removed from the common carotid artery and subclavian artery.

There was no evidence of postoperative cerebral ischemia. The final pathology report confirmed a papillary carcinoma with columnar cell variant. The patient underwent postoperative high-dose radioactive iodine treatment for ablation, and an iodine-131 whole-body scan showed no abnormal uptake in the thyroid bed or other areas. Six years after surgery, the patient remains clinically and biochemically free of disease.

3. Discussion

Although the majority of cases involving angioinvasion to the great vessels in the neck and chest by well-differentiated thyroid cancer usually carry a poor prognosis [1, 2],

aggressive surgery can be curative, or can at least prolong survival, and provides a chance for adjuvant treatment. Therefore, angioinvasion to the great vessels is not a contraindication to surgical extirpation.

Some reports have described surgical treatment for advanced thyroid cancer with resection and reconstruction of the major veins in the neck and chest [3–6]; however, surgical treatment for thyroid cancers invading major arteries has rarely been reported [7, 8].

In the present case, we successfully performed complete surgical removal of the advanced thyroid cancer through en-bloc resection and reconstruction of the major arteries using a synthetic graft.

Preoperative imaging studies are very important for determining the extent of surgery required in each case. Radiological studies should include CT or MRI to evaluate laryngo-tracheal and anterior mediastinal extension. Arteriography is helpful if angioinvasion is suspected because it can assist in differentiating external compression from intra-luminal tumors. However, invasive angiography can be substituted by non-invasive, advanced imaging methods, such as MR angiography. CT and MRI scans are effective, non-invasive methods for evaluating invaded arteries, and can help in preoperative planning. MRI is more effective in assessing invasion to adjacent organs and for planning surgical treatment.

During operations for invasive thyroid cancers, the most important goal of arterial resection and reconstruction is reducing ischemic time. With careful preoperative evaluation, collateral circulation from the circle of Willis may be confirmed. When the collateral circulation is inadequate or the ischemic time is expected to be long, bypass grafts and monitoring with cranial Doppler ultrasound should be used. Another important concern is to avoid tumor spillage and incomplete resection.

After surgery, appropriate adjuvant therapies including high-dose radioactive iodine treatment or external radiation therapy should be administered, and serial evaluation

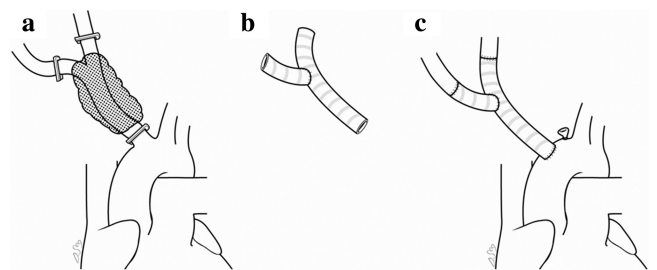


Fig. 2. Surgical procedures for reconstruction of arteries using a synthetic graft (PTFE). (a) En-bloc resection of the tumor, veins, nerves, and brachiocephalic trunk bifurcation site was performed after clamping the midpoint of the right common carotid artery, the proximal portion of the brachiocephalic trunk and the subclavian artery. The proximal stump of the brachiocephalic trunk was closed. (b) A Y-shaped end-to-side anastomosis was made between the PTFE grafts using 6.0 Prolene before anastomosis of the graft and arteries. (c) Reconstruction was performed with the previously made Y-shaped PTFE graft using 6.0 Prolene: the reconstruction order was aorta to graft, graft to right common carotid artery, and graft to right subclavian artery. The graft was anastomosed at the newly made opening in the aorta. The right common carotid artery was reconstructed prior to the right subclavian artery to prevent of cerebral ischemia.

of tumor markers and radioiodine surveillance appropriate for thyroid carcinoma should be performed.

In conclusion, an aggressive surgical approach for locally advanced thyroid cancer invading the great vessels of the neck and mediastinum is an appropriate therapeutic modality for decreasing local recurrence and improving survival rates when performed on appropriate, well-evaluated patients.

Acknowledgement

The authors thank Dong Soo Chang (Chang D.S.) for the illustrations.

References

- [1] Koike E, Yamashita H, Watanabe S, Yamashita H, Noguchi S. Brachiocephalic vein thrombus of papillary thyroid cancer: report of a case. *Surg Today* 2002;32:59–62.
- [2] Gardner RE, Tuttle RM, Burman KD, Haddady S, Truman C, Spurling YH, Wartofsky L, Sessions RB, Ringel MD. Prognostic importance of vascular invasion in papillary thyroid carcinoma. *Arch Otolaryngol Head Neck Surg* 2000;126:309–312.
- [3] Niederle B, Hausmaninger C, Kretschmer G, Polterauer P, Neuhold N, Mirza DF, Roka R. Intraarterial extension of thyroid cancer: technique and results of a radical surgical approach. *Surgery* 1990;108:951–956.
- [4] Sugimoto S, Doihara H, Ogasawara Y, Aoe M, Sano S, Shimizu N. Intraarterial extension of thyroid cancer: a case report. *Acta Med Okayama* 2006;60:135–140.
- [5] Motohashi S, Sekine Y, Iizasa T, Nakano K, Numata T, Fujisawa T. Thyroid cancer with massive invasion into the neck and mediastinal great veins. *Jpn J Thorac Cardiovasc Surg* 2005;53:55–57.
- [6] Patel PC, Millman B, Pellitteri PK, Woods EL. Papillary thyroid carcinoma presenting with massive angioinvasion of the great vessels of the neck and chest. *Otolaryngol Head Neck Surg* 1997;117:S117–S120.
- [7] Urabe Y, Kato S, Fujii M, Akimura T, Kajiwaru K, Fujisawa H, Kitahara T, Suzuki M, Horiike O, Imae Y. Surgical reconstruction of the common carotid artery by an ePTFE graft for invasive thyroid cancer: a case report. *No Shinkei Geka* 2003;31:1105–1109.
- [8] Nomori H, Horio H, Nara S. Synchronous reconstruction of the trachea and innominate artery in thyroid carcinoma. *Ann Thorac Surg* 1995;60:1421–1422.