

Comparison between Posterolateral Fusion with Pedicle Screw Fixation and Anterior Interbody Fusion with Pedicle Screw Fixation in Adult Spondylolytic Spondylolisthesis

Kyung-Soo Suk¹, Chang-Hoon Jeon², Moon-Soo Park³, Seong-Hwan Moon³, Nam-Hyun Kim⁴,
and Hwan-Mo Lee³

¹Department of Orthopaedic Surgery, College of Medicine, Kyung Hee University, Seoul;

²Department of Orthopaedic Surgery, Ajou University School of Medicine, Suwon;

³Department of Orthopaedic Surgery, Yonsei University College of Medicine, Seoul;

⁴Department of Orthopaedic Surgery, Konyang University, Taejeon, Korea.

There have been many reports regarding various operative methods for spondylolytic spondylolisthesis. However, there have been no reports regarding the comparison between posterolateral fusion (PLF) with pedicle screw fixation (PSF) and anterior lumbar interbody fusion (ALIF) with PSF. The purpose of the current study was to compare the clinical outcomes of PLF with PSF and ALIF with PSF, and to help in the selection of treatment options. Fifty-six patients with spondylolytic spondylolisthesis who underwent PLF with PSF (group 1, 35 patients) or who underwent ALIF with PSF (group 2, 21 patients) were studied. Minimum follow-up was 2 years. Demographic variables and disease state were similar for the two groups. We studied operating time, amount of blood loss, duration of hospital stay, clinical outcomes, complications, time at which fusion was complete, fusion rate, and radiological measurements. There were no significant differences between the two groups in terms of the amount of blood loss, duration of hospital stay, back pain, radiating pain, fusion rate, or complication rate. However, in group 2, the operation time and the time at which fusion became complete was longer, and in group 1 there was significant radiological reduction loss. In conclusion, PLF with PSF was just as effective as ALIF with PSF in terms of clinical outcomes, but ALIF with PSF was superior to PLF with PSF in terms of the prevention of reduction loss. Anterior support would be helpful for preventing reduction loss in cases of spondylolytic spondylolisthesis of the lumbar spine.

Key Words: Anterior interbody fusion, lumbar spine, pedicle screw fixation, posterolateral fusion, spondylolytic spondylolisthesis

INTRODUCTION

Spondylolisthesis is defined as forward slippage of one vertebra on another. When this slippage is caused by a defect of the pars interarticularis, it is referred to as spondylolytic spondylolisthesis, which is one of many known causes of low back pain. Wiltse and others have recommended that the vast majority of patients with spondylolisthesis be treated conservatively. The primary indication for surgery in this population is pain refractory to nonoperative treatments. The goals of surgery are to reduce low back and radiating pain, to relieve neurological symptoms, and to improve posture and gait by eliminating instability of the lumbosacral region. The operative procedures consist of decompression and fusion. Decompression methods consist of anterior decompression and posterior decompression. Anterior decompression is an indirect method of decompression, which widens the intervertebral foramen by restoring disc space height. Posterior decompression consists of minimal decompression, which decompresses nerve roots compressed by hypertrophied fibrocartilage in the isthmic defect, and Gill's procedure,¹ which decompresses by total laminectomy and removal of hypertrophied fibrocartilage in the isthmic defect. Fusion methods consist of anterior interbody fusion,²⁻¹⁰ posterior interbody fusion,¹¹⁻¹⁶ and posterolateral fusion¹⁷⁻²⁷ with or without instrumentation. Many research studies have been con-

Received October 16, 2000

Accepted April 9, 2001

ducted on anterior interbody fusion, posterolateral fusion with pedicle screw fixation, anterior interbody fusion with pedicle screw fixation,^{7,28} 360 degree fusion,^{9,22,29,30} decompression alone,^{7,9,10,17,19,22,26,31} and comparisons between the operative methods. However, there are no reports available, which have compared anterior interbody fusion with pedicle screw fixation and posterolateral fusion with pedicle screw fixation. The purpose of this study was to compare the clinical outcomes of posterolateral fusion with pedicle screw fixation and anterior lumbar interbody fusion with pedicle screw fixation, with a view towards helping in the selection of treatment options.

MATERIALS AND METHODS

Fifty-six patients with a minimum follow-up of 24 months, treated by posterolateral fusion with pedicle screw fixation or anterior lumbar interbody fusion with pedicle screw fixation, were prospectively studied. Among the 56 patients, 35 were assigned to the posterolateral fusion with pedicle screw fixation group (group 1) and 21 were assigned to the anterior lumbar interbody fusion with pedicle screw fixation group (group 2). Indications of surgery were back and leg pain, which were refractory to conservative treatment for more than 6 months.

All patients in both groups were decompressed posteriorly by Gill's procedure¹ and fixed using single-level instrumentation with pedicle screws. Fusion was performed with an autograft of iliac

bone in both groups. In group 1, posterolateral fusion was performed after decompression. In group 2, anterior interbody fusion, and then posterior decompression with Gill's procedure and instrumentation were performed in a staged fashion on the same day.

Group 1 consisted of 4 male and 31 female patients. In group 1, the mean follow-up was 38.5 (24 - 96) months; mean age, 51.3 (23 - 70) years; mean depth of pedicle screw insertion in the vertebral body was 70.7 (48.8 - 94.9)% of the anterior-posterior body length. Isthmic defects were located at L3 in 2 cases; L4 in 20 cases; and L5 in 13 cases in group 1. Four patients in group 1 were smokers.

Group 2 consisted of 6 male and 15 female patients, mean follow-up was 34.8 (25-47) months; mean age, 45.9 (18 - 65) years; mean depth of pedicle screw insertion in the vertebral body was 72.0 (51.1 - 87.5)% of the anterior-posterior body length. Isthmic defects were located at L3 in 1 case; L4 in 13 cases; and L5 in 7 cases. Seven patients in group 2 were smokers.

There were no statistically significant differences between the two groups in terms of follow-up ($P=0.488$), age ($P=0.063$), sex ($P=0.152$), the location of isthmic defects ($P=1.000$), number of fusion segments ($P=1.000$), depth of pedicle screw insertion in the vertebral body ($P=0.662$), and smoking ($P=0.080$) (Table 1).

Operating time, amount of blood loss, duration of hospital stay, clinical improvement rate, complications, fusion rate, duration of fusion, and radiological measurements were recorded. Follow-up was performed at 3, 6, and 12 months, and

Table 1. Patient Data

	Group 1	Group 2	Significance (P)
Follow-up (months)	38.5	34.8	0.488
Age (yr)	51.3	45.9	0.063
Sex (M:F)	4:31	6:15	0.152
No. of fusion segments	1.0	1.0	1.000
(Pedicle screw length/length of body)×100	70.7	72.0	0.662
Isthmic defect			
L3	2	1	1.000
L4	20	13	
L5	13	7	
Smoking	4/35	7/21	0.080

every year thereafter.

Clinical outcomes were assessed using a visual analogue scale taking into account back pain and radiating pain. The most severe pain was scored as 10 and the mildest pain was scored as 0. The clinical improvement rate was defined as the difference between the preoperative pain and the postoperative pain scores expressed as a percentage of the preoperative pain score.

Plain film analysis was used to evaluate fusion status. Anteroposterior and lateral flexion and extension radiographs were taken. Less than 4 degrees of motion between the fusion segments on flexion and extension views, in addition to the presence of a contiguous, mature trabecular graft, were required for the fusion to be considered solid or healed. More than 4 degrees of motion or the presence of translation, independent of the appearance of the graft, was considered as a fusion failure. To evaluate fusion between L5 and S1, a lumbar spine AP view with cephalad 40-degree projection was also performed, and when pseudarthrosis was suspected, a tomogram or computed tomogram was taken.

Radiological measurements included anterior disc space height, posterior disc space height, and percentage of vertebral slip, as determined by the Taillard method³² on preoperative, postoperative, 6 month-follow-up, and final follow-up radiographs.

In group 1, the preoperative mean anterior disc space height was 10.4 mm; the mean posterior disc space height was 6.5 mm; and the mean percentage of slip was 21.5%. In group 2, the preoperative mean anterior disc space height was 12.1 mm; the mean posterior disc space height was 7.1mm; and the mean percentage of slip was 17.4%.

There were no statistically significant differences between the two groups in terms of anterior disc space height ($P=0.269$), posterior disc space height ($P=0.370$), or percentage of slip by Taillard's method ($P=0.289$).

Statistical analysis was performed using the Independent sample t-test, the Paired sample t-test, the Chi-square test, and Fisher's exact test.

RESULTS

Clinical results

In group 1, the mean operation time was 202.1 (135 - 315) minutes; amount of blood loss, 925.5 (360 - 1600) ml; duration of hospital stay, 17.4 (12 - 32) days; back pain score, 7.3 (1 - 10) points; radiating pain score, 7.8 (1 - 9.5) points; fusion rate, 94.3% (33/35); and mean duration of fusion, 4.8 (3 - 12) months.

In group 2, the mean operation time was 247.0 (185 - 355) minutes; amount of blood loss, 724.0 (350 - 1800) ml; duration of hospital stay, 19.3 (8 - 65) days; back pain score, 8.0 (2.0 - 10.0) points; radiating pain score, 8.5 (0 - 9.5) points; fusion rate, 100% (21/21); and mean duration of fusion, 6.6 (5 - 11) months.

Operation time ($P=0.000$) and duration of fusion ($P=0.000$) were significantly shorter in group 1 than in group 2. There were no significant differences between the two groups in terms of the amount of blood loss ($P=0.092$), the duration of hospital stay ($P=0.397$), back pain score ($P=0.374$), radiating pain score ($P=0.278$), and fusion rate ($P=0.523$) (Table 2).

Table 2. Clinical Results

	Group 1	Group 2	Significance (P)
Operation time (min)	202.1	247	0.000
Blood loss (ml)	925.5	724	0.092
Hospital stay (days)	17.4	19.3	0.397
Back pain score	7.33	8	0.374
Radiating pain score	7.78	8.45	0.278
Fusion rate (%)	94.3	100	0.523
Fusion time (months)	4.8	6.6	0.000

Radiological analysis

In group 1, the postoperative anterior disc space height was significantly increased, by 1.8mm, compared to the preoperative height (P=0.000). The six month follow-up anterior disc space height was significantly decreased, by 2.5 mm, compared to the postoperative height (P=0.001). No significant change in the anterior disc space height occurred between the 6-month follow-up and the last follow-up (P=0.472) (Fig. 1 A-D).

In group 1, the postoperative posterior disc space height was significantly increased, by 1.5 mm, compared to the preoperative height (P=0.007). Six-month follow-up posterior disc space height was significantly decreased, by 1.2 mm, compared to the postoperative height (P=0.010). No significant change in the posterior disc space height was observed between the 6-month follow-up and the last follow-up (P=0.857).

In group 1, the postoperative degree of slip, by Taillard’s method, was significantly decreased by 8.8% compared to the preoperative degree of slip (P=0.000). However, the six-month follow-up degree of slip by Taillard’s method was significantly increased by 4.7% compared to the postoperative degree of slip (P=0.010). No significant change in degree of slip, by Taillard’s method, was found between the 6-month follow-up and the last follow-up (P=0.852) (Table 3). In group 2, the postoperative anterior disc space height was significantly increased by 2.4 mm compared to the preoperative height (P=0.004). Radiologically, anterior disc space height did not change significantly over the postoperative to the 6-month follow-up period (P=0.109) or the 6 month follow-up to the last follow-up period (P=0.717) (Fig. 2 A-D).

In group 2, there were no significant changes in posterior disc space heights comparing preoperative radiography to postoperative radiography

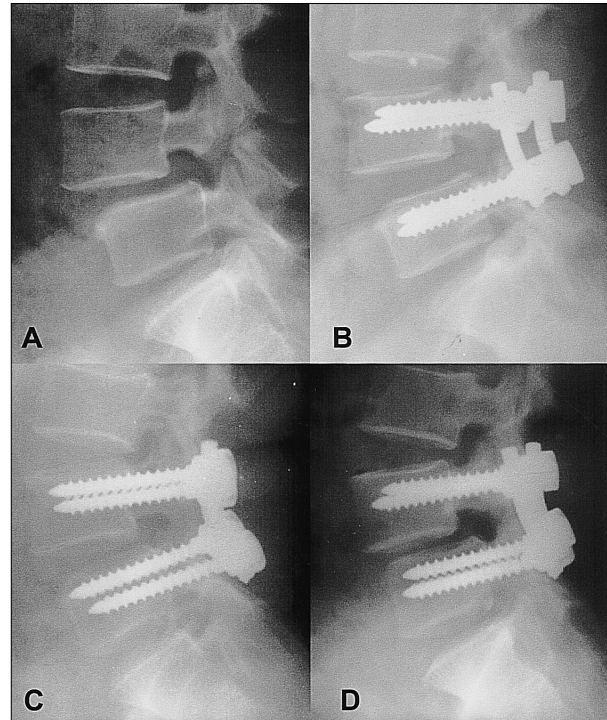


Fig. 1. A. Preoperative lateral radiography of a 40-year-old woman with spondylolytic spondylolisthesis shows anterior slip of L4 and narrowing of the L4-5 disc space. B. Postoperative lateral radiography of a 40-year-old woman treated by posterolateral fusion with pedicle screws shows good reduction and the restoration of disc space. C. Postoperative 6-month follow-up lateral radiography of the lumbar spine shows loss of reduction, narrowing of disc space, and breakage of the left L5 pedicle screw. D. Postoperative 35-month follow-up lateral radiography of the lumbar spine shows further loss of reduction, narrowing of disc space, and kyphotic deformity of L4-5.

(P=0.112), postoperative radiography to 6-month follow-up (P=0.090), and 6-month follow-up to the last follow-up (P=0.789).

In group 2, the postoperative degree of slip by Taillard’s method was significantly decreased by 6.7% compared to the preoperative degree of slip (P=0.002). No significant changes in the percentage of slip by Taillard’s method were observed

Table 3. Radiological Measurements of Group 1

	Preoperative	Postoperative	6 months	Last F-U
Anterior disc height (mm)	10.4	12.2	10	9.9
Posterior disc height (mm)	6.5	8	6.8	6.7
Degree of slip by Taillard (%)	21.5	12.7	17.4	17.5

radiologically over the postoperative to 6-month follow-up ($P=0.166$) or the 6-month follow-up to the last follow-up ($P=0.566$) periods (Table 4).

Complications

Complications included one pulmonary embolism, one duodenal ulcer, one wound infection, one donor site infection, and one metal failure in group 1.

There were 3 wound infections in group 2.

DISCUSSION

Posterolateral fusion of the lumbar spine has been a widely performed procedure. Pedicle screw fixation prevents progression of deformity, decreases postoperative back pain, and allows full nerve decompression without fear of residual instability or progressive slippage. The correction of slip angle (kyphosis) restores the body's central axis over the sacrum, and greatly reduces the bending moment and tensile stress that works against the lumbosacral graft. Moreover, correcting the slip itself restores axial loading across the lumbosacral interspace. Pedicle screw fixation of the aligned spine then eliminates shear. Therefore, short segment fusion is possible, the fusion rate is increased, normal spine mechanics and body posture are restored, and the patient's self-image is improved.

Many studies have been conducted on the topic of instrumented posterolateral fusion. The majority of these have reported better clinical outcome and a higher fusion rate by the addition of instrumentation.^{16,18,23-25,27,33-36} However, some authors have reported no significant differences in terms of the clinical outcome and fusion rate between instrumented and non-instrumented groups.^{19,26}

The subjects of this study were middle-aged patients (i.e., 51.3 years in group 1, and 45.9 years in group 2) who complained of back pain and/or radiating pain and/or neurologic claudication. Therefore, sufficient decompression and fusion were necessary components in the selection of treatment options. In group 1, posterior decompression with Gill's procedure and instrumented posterolateral fusion was performed.

The advantages of anterior interbody fusion are the direct observation of the anteriorly displaced

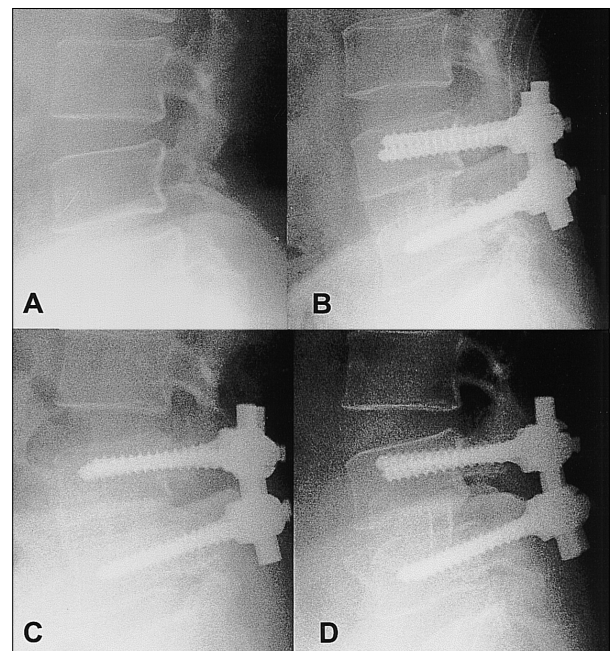


Fig. 2. A. Preoperative lateral radiography of a 37-year-old woman with spondylolytic spondylolisthesis shows anterior slip of L4 and narrowing of the L4-5 disc space. B. Postoperative lateral radiography of a 40-year-old woman treated with anterior interbody fusion with pedicle screws shows good reduction and the restoration of disc space. C. Postoperative 6-month follow-up lateral radiography of the lumbar spine shows a slight loss of reduction. However, disc space height was well preserved. D. Postoperative 24-month follow-up lateral radiography of the lumbar spine shows good fusion of L4-5 and a well preserved disc space height.

Table 4. Radiological Measurements of Group 2

	Preoperative	Postoperative	6 months	Last F-U
Anterior disc height (mm)	12.1	14.5	14.1	13.9
Posterior disc height (mm)	7.1	9	7.5	7.4
Degree of slip by Taillard (%)	17.4	10.7	10.8	10.4

vertebral body; the avoidance of injury to posterior supporting ligaments, dural sac, or nerve roots; and a reduced need for transfusion. In 1999, Kim and Lee³¹ compared the results of anterior interbody fusion alone and posterolateral fusion with pedicle screw fixation for isthmic spondylolisthesis in adults. They reached the conclusion that there were no statistically significant differences in terms of clinical results between the two groups. However, posterior fixation is biomechanically necessary for posterior compression after anterior interbody fusion, which is compatible for tension band, load-sharing principle.² The advantage of adding instrumentation is that it reduces the need for external immobilization and prevents the extrusion of grafted tricortical bone.

Anterior interbody fusion is an indirect method of decompression, which widens the intervertebral foramen by restoring the intervertebral disc space. However, spondylolytic spondylolisthesis of middle-aged patients frequently combined with spinal stenosis and shows compression of the nerve root by hypertrophied fibrocartilage at the isthmic defects. Therefore, anterior decompression alone is frequently insufficient and posterior decompression is necessary. In group 2, anterior decompression was followed by posterior decompression (Gill's procedure) and instrumentation with pedicle screws.

In 1996, Wang et al.²⁸ reported a 95% satisfactory clinical outcome and a 95% fusion rate in patients with spondylolysis and grade 1 spondylolisthesis who were treated by anterior interbody fusion with pedicle screw fixation. Their study showed a very high satisfactory clinical outcome and an equally high fusion rate. However, the treatment method used was not compared to the proven methods for treating spondylolisthesis. In our study, we compared anterior interbody fusion with pedicle screw fixation to posterolateral fusion with pedicle screw fixation.

In 1997, Muschik et al.⁷ reported that anterior spondylodesis including posterior instrumentation and reduction was superior to simple anterior fusion in situ for the normalization of the lumbosacral profile and the osseous consolidation of the spondylodesis. However, this result was not reflected in the clinical evaluation. In contrast,

Roca et al.¹⁵ reported that circumferential in situ fusion without reduction was a safe and effective technique for managing severe spondylolisthesis. In our study, we performed spontaneous postural reduction by extension of the hip and reduction by distraction of the pedicle screw system in group 1. In group 2 reduction was performed by inserting a tricortical bone into the disc space, which was 5 mm bigger than the height of the disc space, and not by distracting with the pedicle screw system.

Operation time was longer in group 2 than in group 1, which was thought to be due to anterior interbody fusion time in the former group.

The fusion time was also longer in group 2 than in group 1, and this was rationalized on the basis of the cancellous chip bone graft performed in group 1, which both enables revascularization into the graft and facilitates fusion by osteogenesis of the mesenchymal stem cells originating from the decorticated transverse process. In contrast, in group 2, tricortical autoiliac bone graft was performed, and therefore, revascularization into the graft took more time and fusion was accomplished by creeping substitution rather than direct osteogenesis. There were no significant differences between the two groups in terms of the amount of blood loss, the duration of hospital stay, back pain score, radiating pain score, or the fusion rate.

In this study, we measured the anterior disc space height, posterior disc space height, and the percentage of slippage by Taillard's method on preoperative, postoperative, 6-month follow-up, and 2-year follow-up, and final follow-up radiography. Measurements were compared and analyzed by using the paired sample t-test. In group 1, disc space height increased and the degree of slippage was reduced postoperatively. However, a significant reduction loss was found 6 months postoperatively, though no significant subsequent reduction loss was found from 6 months after the operation to the final follow-up (more than 24 months), which was believed to be due to the progression of reduction loss until complete fusion had been achieved. In group 2, there was no reduction loss during the follow-up period, probably because the anterior support by anterior interbody fusion prevented reduction loss. Therefore, the radiological outcome of group

2 was superior to that of group 1.

As mentioned above, the reduction obtained by operation was lost within 6 months after operation in group 1. However, there were no significant differences between the two groups in terms clinical outcomes, including back pain and radiating pain, which was attributed to sufficient decompression of nerve roots, including total laminectomy, complete removal of hypertrophied fibrocartilage by Gill's procedure, and foraminotomy.

Therefore, we suggest that in young active patients anterior interbody fusion is beneficial to prevent long-term instabilities, but in relatively older less active patients, simple decompression and posterolateral fusion is recommended, because it is relatively simple and easy requiring only a single incision technique.

Hwan - Mo Lee, M.D.

*Department of Orthopaedic Surgery,
Yonsei University College of Medicine,
C.P.O. Box 8044, Seoul 120-752, Korea.
Tel: 82-2-361-5640, Fax: 82-2-363-1139,
E-mail: hwanlee@yumc.yonsei.ac.kr*

REFERENCES

- Gill CG, Manning JG, White HL. Surgical treatment of spondylolisthesis without fusion. *J Bone Joint Surg* 1955;37A:493-520.
- Bridwell KH. Load sharing principles: the role and use of anterior structural support in adult deformity. *Instr Course Lect* 1996;45:109-15.
- Christensen FB, Karlsmose B, Hansen ES, Bunge CE. Radiological and functional outcome after anterior lumbar interbody spinal fusion. *Eur Spine J* 1996;5:293-8.
- Kim NH, Choi CH. Anterior interbody fusion in spondylolisthesis. *J Korean Orthop Assoc* 1988;23:789-806.
- Kim NH, Choi CH, Park SJ. The comparison of fusion rate in anterior interbody fusion between infected and non-infected disease of the spine. *J Korean Spine Surg* 1994;1:54-65.
- Kim NH, Kim DJ. Anterior interbody fusion for spondylolisthesis. *Orthopaedics* 1991;14:1069-75.
- Muschik M, Zippel H, Perka C. Surgical management of severe spondylolisthesis in children and adolescents. Anterior fusion in situ versus anterior spondylodesis with posterior transpedicular instrumentation and reduction. *Spine* 1997;22:2036-42.
- Pfeiffer M, Griss P, Haake M, Kienapfel H, Billion M. Standardized evaluation of long-term results after anterior lumbar interbody fusion. *Eur Spine J* 1996;5:299-307.
- Tiusanen H, Schlenzka D, Seitsalo S, Poussa M, Osterman K. Results of a trial of anterior or circumferential lumbar fusion in the treatment of severe isthmic spondylolisthesis in young. *J Pediatr Orthop (Part B)* 1996;5:190-4.
- Wimmer C, Krismer M, Gluch H, Sterzinger W, Ogon M. Advantages and disadvantages of retro-and transperitoneal approach for fusion of the presacral intervertebral disk. *Orthopade* 1997;26:563-7.
- Bohnen IM, Schaafsma J, Tonino AJ. Results and complication after posterior lumbar spondylodesis with the "Variable screw placement spinal fixation system". *Acta Orthop Belg* 1997;63:67-73.
- Esses SI, Natout N, Kip P. Posterior interbody arthrodesis with a fibular strut graft in spondylolisthesis. *J Bone Joint Surg* 1995;77A:172-6.
- Fabris DA, Costantini S, Nena U. Surgical treatment of severe L5-S1 spondylolisthesis in children and adolescents. Results of intraoperative reduction, posterior interbody fusion, and segmental pedicle fixation. *Spine* 1996;21:728-33.
- Kluger P, Weidt F, Puhl W. Spondylolisthesis and pseudospondylolisthesis. Treatment by segmental reposition and interbody fusion with fixateur interne. *Orthopade* 1997;26:790-5.
- Roca J, Uberna MT, Caceres E, Iborra M. One-stage decompression and posterolateral and interbody fusion for severe spondylolisthesis. An analysis of 14 patients. *Spine* 1999;24:709-14.
- Suk SI, Lee CK, Kim WJ, Lee JH, Cho KJ, Kim HG. Adding posterior lumbar interbody fusion to pedicle screw fixation and posterolateral fusion after decompression in spondylolytic spondylolisthesis. *Spine* 1997;22:210-9.
- Carragee EJ. Single-level posterolateral arthrodesis, with or without posterior decompression, for the treatment of isthmic spondylolisthesis in adults. A prospective, randomized study. *J Bone Joint Surg* 1997;79A:1175-80.
- Chen WJ, Niu CC, Chen LH, Shih CH. Survivalship analysis of DKS instrumentation in the treatment of spondylolisthesis. *Clin Orthop* 1997;339:113-20.
- Christensen FB, Thomsen K, Eiskjaer SP, Hansen ES, Fruensgaard S, Gelinick J, et al. The effect of pedicle screw instrumentation on posterolateral spinal fusion. A prospective, randomized study with a two-year follow-up. *Ugeskr Laeger* 1999;161:1920-5.
- Deguchi M, Rapoff AJ, Zdeblick TA. Posterolateral fusion for isthmic spondylolisthesis in adults: analysis of fusion rate and clinical results. *J Spinal Disord* 1998;11:459-64.
- de Loubresse CG, Bon T, Deburge A, Lassale B, Benoit M. Posterolateral fusion for radicular pain in isthmic

- spondylolisthesis. *Clin Orthop* 1996;323:194-201.
22. Krismer M, Auckenthaler T, Gruber R, Wimmer C, Sterzinger W, Ogon M. Lumbar fusion in adults-dorsal or combined ventral/dorsal approach? *Orthopade* 1997; 26:568-71.
 23. Lisai P, Rinonapoli G, Doria C, Manunta A, Crissantu L, De Santis E. The surgical treatment of spondylolisthesis with transpedicular stabilization : a review of 25 cases. *Chir Organi Mov* 1998;83:369-74.
 24. Nooraie H, Ensafdaran A, Arastech MM. Surgical management of low-grade lytic spondylolisthesis with C-D instrumentation in adult patients. *Arch Orthop Trauma Surg* 1999;119:337-9.
 25. Pihlajamaki H, Bostman O, Ruuskanen M, Myllynen P, Kinnunen J, Karaharju E. Posterolateral lumbosacral fusion with transpedicular fixation: 63 consecutive cases followed for 4 years. *Acta Orthop Scand* 1996;67: 63-8.
 26. Thomsen K, Christensen FB, Eiskjaer SP, Hansen ES, Fruensgaard S, Bunge CE. The effect of pedicle screw instrumentation on functional outcome and fusion rates in posterolateral lumbar spinal fusion: a prospective, randomized clinical study. *Spine* 1997;22:2813-22.
 27. Wang PJ, Chen WJ, Chen LH, Niu CC. Spinal fusion and pedicle screw instrumentation in the treatment of spondylolisthesis over the age of 60. *Chang Keng I Hsueh Tsa Chih* 1998;21:436-41.
 28. Wang JM, Kim DJ, Yun YH. Posterior pedicular screw instrumentation and anterior interbody fusion in adult lumbar spondylolysis or grade I spondylolisthesis with segmental instability. *J Spinal Disord* 1996;9:83-8.
 29. Laursen M, Thomsen K, Eiskjaer SP, Hansen ES, Bunge CE. Functional outcome after partial reduction and 360 degree fusion in grade III-V spondylolisthesis in adolescent and adult patients. *J Spinal Disord* 1999;12:300-6.
 30. Gertzbein SD, Betz R, Clements D, Errico T, Hammerberg K, Robbins S, et al. Semirigid instrumentation in the management of lumbar spinal condition combined with circumferential fusion. A multicenter study. *Spine* 1996;21:1918-26.
 31. Kim NH, Lee JW. Anterior interbody fusion versus posterolateral fusion with transpedicular fixation for isthmic spondylolisthesis in adults. *Spine* 1999;24:812-6.
 32. Taillard W. Le spondylolisthesis chez l'enfant et l'adolescent. *Acta Orthop Scand* 1954;24:115-20.
 33. Ricciardi JE, Pflueger PC, Isaza JE, Whitecloud TS 3rd. Transpedicular fixation for the treatment of isthmic spondylolisthesis in adults. *Spine* 1995;20:1917-22.
 34. Schnee CL, Freese A, Ansell LV. Outcome analysis for adults with spondylolisthesis treatment with posterolateral fusion and transpedicular screw fixation. *J Neurosurg* 1997;86:56-63.
 35. Stambough JL. Lumbosacral instrumented fusion : analysis of 124 consecutive cases. *J Spinal Disord* 1999;12: 1-9.
 36. Thalgott JS, Sasso RC, Cotler HB, Aebi M, LaRocca SH. Adult spondylolisthesis treated with posterolateral lumbar fusion and pedicular instrumentation with AO DC plates. *J Spinal Disord* 1997;10:204-8.