Reconstruction of vocal fold using a fat block implant following cordectomy through a minithyrotomy approach in a rabbit model

Seung Won Lee

Department of Medicine
The Graduate School, Yonsei University

Reconstruction of vocal fold using a fat block implant following cordectomy through a minithyrotomy approach in a rabbit model

Directed by Professor Eun Chang Choi

The Doctoral Dissertation
Submitted to the Department of Medicine,
The Graduate School of Yonsei University
In partial fulfillment of the requirements for the degree
of Doctor of Philosophy of Medical Science

Seung Won Lee

December 2010

This certifies that the Doctoral Dissertation of Seung Won Lee is approved.

Thesis Supervisor: Eun Chang Choi

Thesis Committee Member #1: Young Mo Kim

Thesis Committee Member #2: Young Ho Kim

Thesis Committee Member #3: Kyung Ah Park

Thesis Committee Member#4: Sun Joon Bai

The Graduate School
Yonsei University

December 2010

ACKNOWLEDGEMENTS

I first thank God for giving me the privilege of becoming a physician and the opportunity to further my education in the Head, Neck, and Surgery field. I especially thank Prof. Eun Chang Choi for his guidance and encouragement. This research work would not have been possible without his encouragement. Also I am grateful to Profs. Kyung Ah Park, Young Mo Kim, Young Ho Kim, Sun Joon Bai for their teaching and valuable comments in writing this thesis. If my late father and mother were alive, they will be proud of me to receive a Ph.D. degree at Yonsei University. I dedicate the fruits of this research to my beloved my late father and mother. Without their support from the heaven, this work would not have been possible.

<TABLE OF CONTENTS>

LIST OF FIGURES

LIST OF TABLES

<ABSTRACT>

Reconstruction of vocal fold using a fat block implant following cordectomy through a minithyrotomy approach in a rabbit model

Seung Won Lee

Department of Medicine

The Graduate School, Yonsei University

(Directed by Professor Eun Chang Choi)

Following transoral laser surgery for glottic cancer, the vocal fold musculature is usually resected, resulting in a concave configuration of the fibrotic neocords, leading to incomplete glottal closure.[1] This causes the voice to become hoarse and breathy, and the patient's quality of life is worsened despite the cancer possibly being cured.

Several voice restoration techniques, such as injection laryngoplasty and medialization thyroplasty, have been introduced to reestablish glottal competency.[2] However, these techniques only move the fibrotic vocal fold to the midline and do not in fact correct the excavated fibrotic vocal fold.

Minithyrotomy is a novel approach that provides direct access to the lamina propria and vocalis muscle without requiring incision of the vocal fold mucosa. This procedure can create a 'tunnel pocket' space within the fibrotic vocal fold before insertion of implant materials. Thus, it is possible to place the vocal fold bulge at the midline and to directly correct the concave fibrotic vocal fold.[3]

Twenty five adult female conditioned laboratory rabbits were used for this study. Minithyrotomy vocal fold reconstruction was performed using a single fat block implant or hyaluronic acid derivatives (®Rofilan, Rofil Medical International NV, Breda, Netherlands) 3 months after cordectomy. For the single fat block minithyrotomy reconstruction, a rabbit larynx was harvested at 1 and 6 months

following minithyrotomy, and control rabbit larynges were harvested at 4 and 9 months after cordectomy. For the hyaluronic acid minithyrotomy reconstruction, rabbit larynx was harvested at 3 months following minithyrotomy.

To compare total square amount and density of vocal folds between the minithyrotomy and cordectomy group, hematoxylin and eosin, masson's trichrome, and alcian blue staining were used. Based on histological examinations, minithyrotomy vocal fold reconstruction postoperatively restored vocal fold bulkiness and maintained volume for up to postoperative 6 months, compared with the cordectomy group ($P < 0.05$). In light of the surgical manipulation, the procedure also did not aggravate scarring of the cordectomized vocal fold.

Based on findings of this study, minithyrotomy vocal fold reconstruction using an autologous fat block may soon be feasible in humans undergoing rehabilitation for post-cordectomy dysphonia without causing additional damage to the vocal folds.

Key words: vocal cords, defects, reconstructive procedure

Reconstruction of vocal fold using a fat block implant following cordectomy through a minithyrotomy approach in a rabbit model

Seung Won Lee

Department of Medicine
The Graduate School, Yonsei University
(Directed by Professor Eun Chang Choi)

I. INTRODUCTION

Following transoral laser surgery for glottic cancer, the vocal fold musculature is usually resected, resulting in a concave configuration of the fibrotic neocords, leading to incomplete glottal closure.[1] This causes the voice to become hoarse and breathy, and the quality of life of patients are worsened despite of curing the cancer. Several voice restoration techniques, such as injection laryngoplasty and medialization thyroplasty, have been used to reestablish glottal competency by augmentation of the paraglottic space or medialization of the excavated vocal fold.[1,2,4] However, these techniques only move the fibrotic vocal fold to the midline and do not actually correct the excavated vocal fold.

Minithyrotomy is a novel approach that allows direct access to the lamina propria and vocalis muscle without mucosal incision.[5] This procedure can create a ‘tunnel pocket’ space within the fibrotic vocal fold before insertion of implant materials. Thus, it is possible to place the vocal fold bulge at the midline and directly correct the concave fibrotic vocal fold.[3]

Vocal fold reconstruction using a minithyrotomy approach is at least theoretically ideal for post-cordectomy scar patients, but there is no animal-based evidence for the procedure. Thus, animal models are mandatory to examine the mechanism and results of early and late minithyrotomy vocal fold reconstruction

before their clinical use. In this study, single fat block or hyaluronic acid derivatives (Rofilan, Rofil Medical International NV, Breda, Netherlands) were used for implant materials. Implantations using fat blocks show less absorption than conventional injections using lipoaspiration fat [6], and hyaluronic acid derivatives are the most common commercially available vocal fold injection fillers. The aim of this study was to demonstrate the efficacy of minithyrotomy vocal fold reconstruction in a rabbit model by comparing the vocal fold total square amount and the density of scars between the MT group (minithyrotomy vocal fold reconstruction using fat block group) and the CT group (cordectomy group).

II. MATERIALS AND METHODS

Animals

Twenty-five adult female conditioned laboratory rabbits were used for this study (body weight ranged, 2.5-3 kg). All animal surgery and care procedures were carried out in accordance with our institutional policy on the care of animals. The experimental group consisted of 10 fat block implant rabbits 1 and 6 months after minithyrotomy vocal fold reconstruction and five hyaluronic acid derivative implant rabbits (HA group) 3 months after minithyrotomy. The control group consisted of 10 cordectomy rabbits 4 and 9 months after cordectomy compared with the corresponsive period for each MT group, which had five rabbits each. Minithyrotomy was performed 3 months after cordectomy, and the left side was the experimental side in each experiment.

Surgical Procedures

Rabbits were anesthetized by administering an intramuscular injection mixture of xylazine HCl at 5 mg/kg and ketamine hydrochloride at 50 mg/kg. A 7.5-cm nasal speculum was introduced through the oral cavity to expose the vocal folds.

A 30°, 2.7 mm × 30 cm telescope (Karl Storz Co. Tuttlingen, Germany), coupled with a camera, was passed through the speculum to maximize visualization. A cordectomy was performed including the vocalis muscle, with bovie electrocautery (Conmed, Utica, NY, USA) in a 25-watt cutting mode. To injure the vocal fold uniformly, contact was made with the membranous portion of the vocal folds three times for 1-2 s. [7]

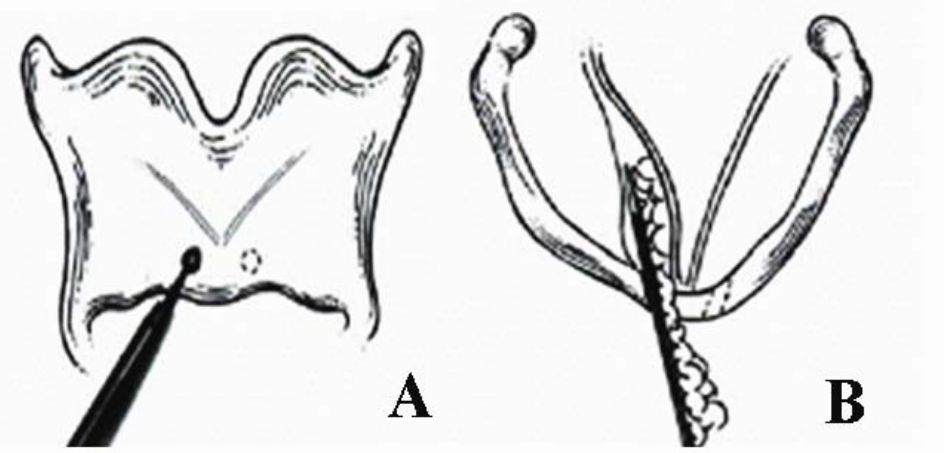

Fig. 1. Operative diagram of minithyrotomy vocal fold reconstruction using single fat block. Make a minithyrotomy opening 2-3 mm lateral to the midline (A) and graft the fat block to the tunnel pocket space (B).

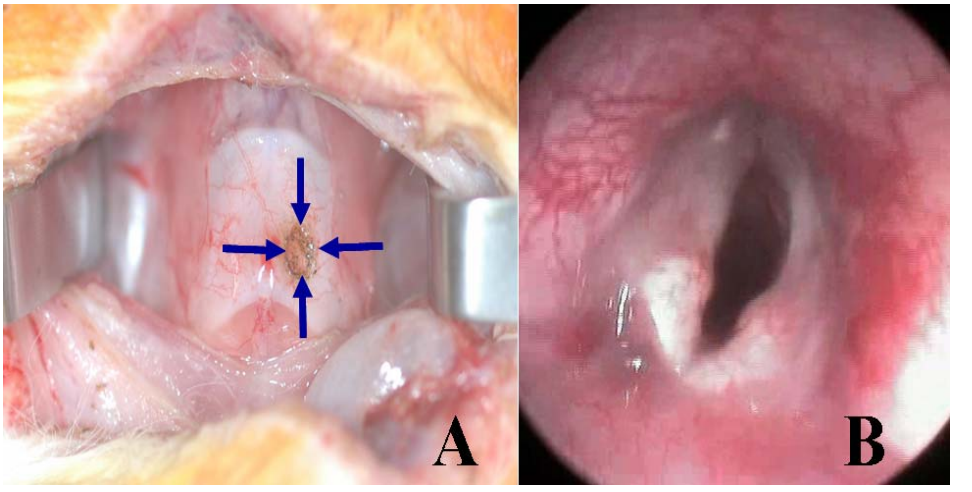

Fig. 2. Intraoperative photograph of the minithyrotomy opening site (arrow) (A) and the reconstructed left vocal fold with fat block through the minithyrotomy opening site (B).

Minithyrotomy Vocal Fold Reconstruction Technique (Fig. 1)

1. Make a horizontal incision at the level of the lower edge of the thyroid cartilage.
2. Harvest the fat block from the subcutaneous tissue in strips comparable to the length of the vocal fold.
3. Make a minithyrotomy opening 2-3 mm lateral to the midline using bovie electrocautery (Fig. 2).
4. Perform a blunt dissection using a curved micropick for otologic surgery that is parallel to the vocal fold edge to create a 'tunnel pocket' space under the 30° endoscope monitoring. Care is taken to avoid perforation of the vocal fold mucosa.
5. Graft the fat block to the 'tunnel pocket' space for the MT group, and inject hyaluronic acid through the minithyrotomy opening for the HA group.
6. Approximately 30% overcorrection was made, in consideration of postoperative absorption.
7. Close the minithyrotomy opening site with bone wax.

Tissue Preparation

Coronal sections were made from whole larynges, and slides that included the middle of the membranous vocal folds were subsequently used for histological analyses.[8]

Rabbits were sacrificed for laryngeal harvest at four points after making a cordectomy wound (1 and 6 months after minithyrotomy for the MT group and 4 and 9 months after cordectomy for the CT group). For the HA group, rabbits were sacrificed at 3 months after minithyrotomy. The early wound healing period

(early period) and late wound healing period (late period) were defined as post-minithyrotomy1 and 6 months, respectively.[9]

Staining Method

Laryngeal tissues were fixed in 10% formaldehyde and then embedded in paraffin. 6 μm sections were prepared for histological examination. Hematoxylin and eosin (HE) staining was used to assess the total amount of squares between the MT, HA, and CT group. Alcian blue staining was used to detect hyaluronic acid (HA), and Masson's trichrome to detect collagen.[8]

The total amounts of HA and collagen in the lamina propria and vocalis muscle were examined histologically, and comparisons were made between the MT, HA, and CT groups. The lamina propria and vocalis muscle of each vocal fold was examined at a magnification of ×10, and images were captured with a Nikon Eclipse 80i microscope (Nikon Corporation, Japan), Jenoptik color camera (model ProgRes C10 Plus, Jena, Germany), and the Image J software (Image J 1.43u; National Institutes of Health, Bethesda, MD). Adobe PhotoShop image analysis software (Adobe Systems Inc, San Jose, CA) was used to measure the density and square ratios of stained regions of the vocal fold.[10] The ratios of pixels in the stained area relative to the total number of pixels in the lamina propria and vocalis muscle were indicators of each molecule's density and were considered to indicate the density of HA or collagen.[11,12] To minimize measurement bias, all measurements were made by one pathologist who analyzed the images and had no knowledge of which groups the specimens belonged to.[13] Statistical comparisons were made between the MT, HA, and CT groups using the Mann Whitney U-test. Differences at $P < 0.05$ were regarded as statistically significant.

CD34 Immunohistochemical Study

Sections were incubated with primary antibody for 30 min at room temperature and washed. CD34 (monoclonal, 1:50, Dako, CA, USA) was the primary antibody, and anti-rabbit and anti-mouse immunoglobulin G (Envision kit, Glostrup, Denmark) were the secondary antibodies for detection of bound primary antibodies. Secondary antibodies were applied for 30 min at room temperature and washed using TBS buffer. For the chromogen, 3, 3'-diaminobenzidinetetrahydrochloride was used, and a Meyer's hematoxylin counterstain was subsequently applied. For a negative control, the primary antibody was omitted and replaced with antibody diluent.

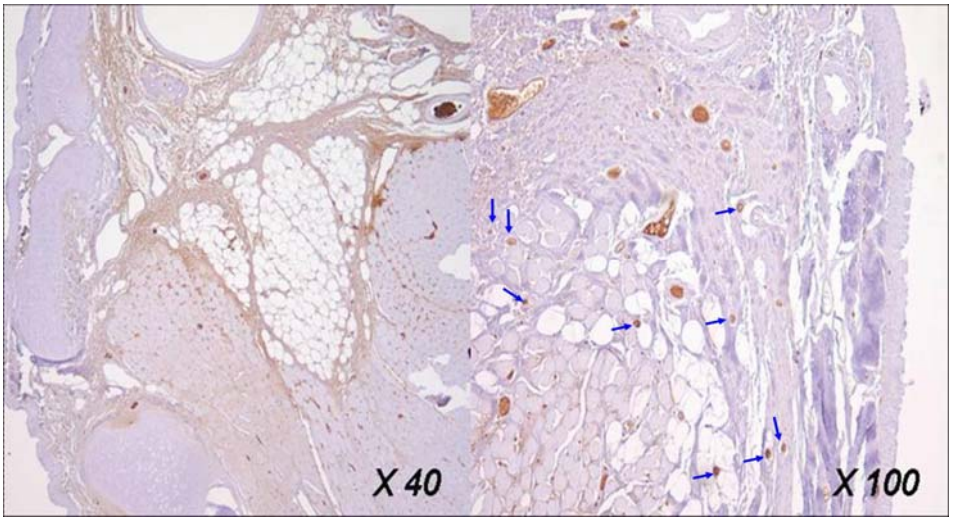

Fig. 3. CD34 immunohistochemical staining was used to detect the neovascularization status, a factor known to favor chronicity of the inflammatory process. Single endothelial cells or clusters of endothelial cells, discrete areas stained with CD34 were counted as individual microvessels.(arrows)

Microvessel Counting

All scoring and interpretation of the immunohistochemical results were done by one examiner with no knowledge of the clinical data. Whether they were single endothelial cells or clusters of endothelial cells, discrete areas stained with CD34 were counted as individual microvessels. A high-power magnification (×100)

was used to count vessels in three different fields and the average was calculated (Fig. 3).

III. RESULTS

Hematoxylin Eosin Staining

Total squares of vocal folds in the MT group were significantly wider ($P < 0.05$) than in the CT group in the early period, and this remained stable ($P < 0.05$) until 6 months after the minithyrotomy (Fig. 4. 5).

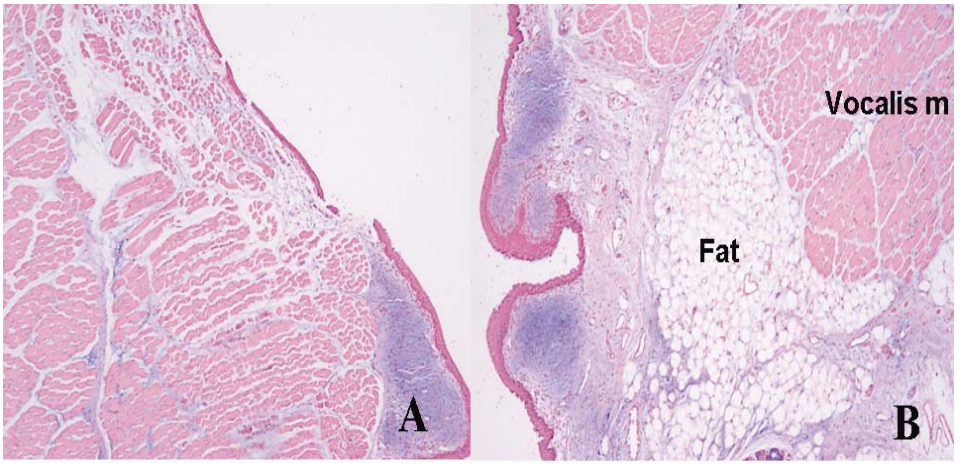

Fig. 4. H-E staining of the CT group (A) and MT group (B) at post-minithyrtomy 6 months. The MT group (B) showed the well grafted fat cell in the vocal fold. (× 40)

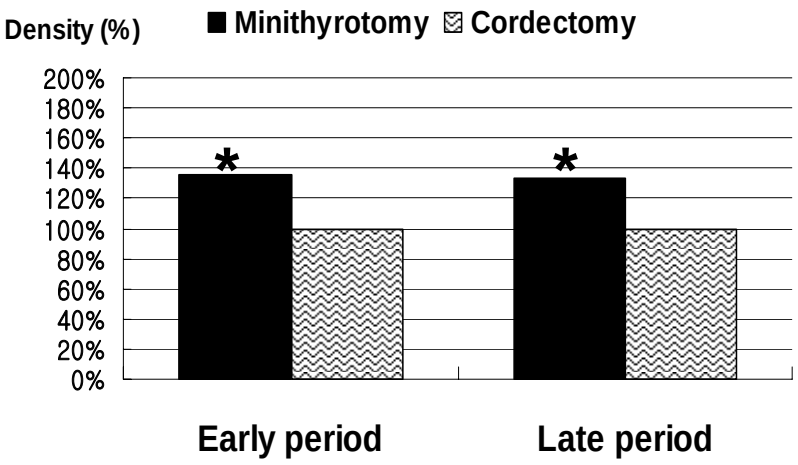

Fig. 5. Ratios of total squares in the MT and CT groups. Total squares of vocal folds in the MT group were significantly wider ($P < 0.05$) than in the CT group at post-minithyrotomy 1 and 6 months

Early period: post-minithyrotomy 1 month for the MT group; post-cordectomy 4 months for the CT group.

Late period: post-minithyrotomy 6 months for the MT group; post-cordectomy 9 months for CT group.

MT group: minithyrotomy vocal fold reconstruction using fat block group.

CT group: cordectomy-only group.

* $P < 0.05$.

Alcian blue and Masson Trichrome Staining

At 1 and 6 months after the minithyrotomy in the MT group, HA density decreased slightly, and collagen density increased slightly, compared with the CT group. However, the differences between two groups were not statistically significant (Fig. 6, 7, 8).

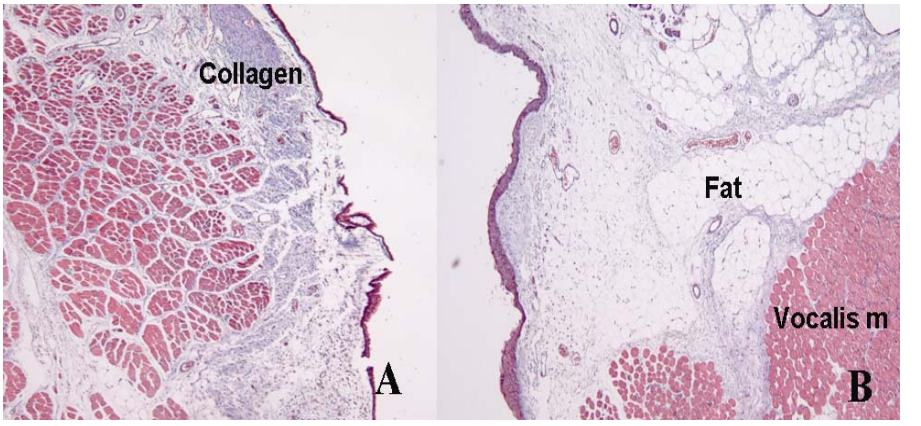

Fig. 6. Masson trichrome staining of the CT group (A) and MT group (B) at post-minithyrtomy 6 months. The MT group showed more wider the vocal fold volume than the CT group without increasing the density of collagen. (× 40)

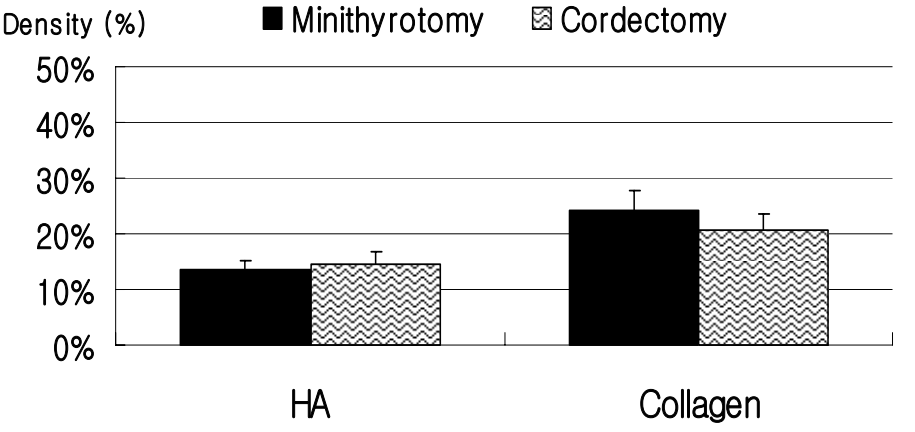

Fig. 7. Results of histological image analysis of HA and collagen density for the MT group post-minithyrotomy 1 month and post-cordectomy 4 months for the CT group. Density of HA and collagen for the MT group were not significantly different compared with the CT group for the early period (bar indicates standard deviation).

MT group: minithyrotomy vocal fold reconstruction using a fat block group.

CT group: cordectomy-only group.

HA: hyaluronic acid

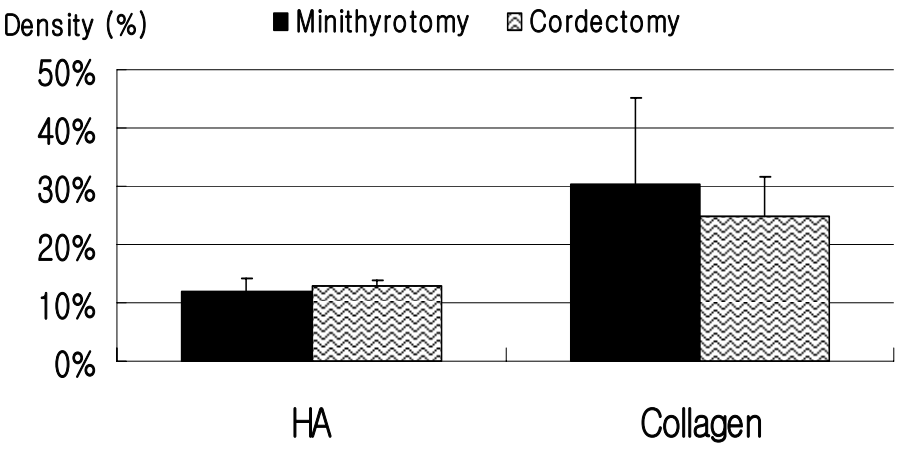

Fig. 8. Results of histological image analysis of HA and collagen density post-minithyrotomy 6 months for the MT group and post-cordectomy 9 months for the CT group. HA and collagen density for the MT group are not significantly different as compared to the CT group for the late period (bar indicates standard deviation).

MT group: minithyrotomy vocal fold reconstruction using fat block group.

CT group: cordectomy-only group.

HA: hyaluronic acid

CD 34 Immunohistochemical Staining

The average ratios of microvascular densities of vocal fold area were not significantly different between the MT and CT groups for both early and late wound-healing periods (Table I).

Table I. Microvascular density using CD34 immunohistochemical staining

	MT group	CT group	HA group*	
Early period	19.9 ± 7.0	19.1 ± 4.8	19.5 ± 7.0*	$P > 0.05$
Late period	14.4 ± 3.6	15.7 ± 5.0		$P > 0.05$

Early period: post-minithyrotomy 1 month for the MT group; post-cordectomy 4 months for the CT group.

Late period: post-minithyrotomy 6 months for the MT group; post-cordectomy 9 months for the CT group.

MT group: minithyrotomy vocal fold reconstruction using fat block group

CT group: cordectomy-only group.

HA group*: minithyrotomy vocal fold reconstruction using hyaluronic acid post-minithyrotomy 3 months.

Minithyrotomy Vocal Fold Reconstruction with HA

Total squares of vocal folds in the HA group were wider post-minithyrotomy, 3 months compared with that of the CT group post-cordectomy 4 months. However, there was no significant difference between the two groups (P > 0.05).

HA density decreased slightly, while collagen density increased slightly for the HA group, compared with the CT group post-cordectomy 4 months. However, the differences between the two groups were not significant (P > 0.05).

IV. DISCUSSION

Over the last 30 years, the introduction of the microscope and CO_2 laser has expanded the role of transoral endoscopic resection in the management of glottic cancer. When the vocalis muscle was not resected, phonosurgical reconstruction was usually not required. However, deeper resection of the vocalis muscle results in a healed concave-shaped neocord. An excavated fibrotic neocord results in incomplete glottal closure, and this leads to hoarseness, and a poorer quality of

life for the patient.[14] Several rehabilitation techniques, such as injection laryngoplasty, medialization thyroplasty, and anterior commissure laryngoplasty, have been used to restore glottal competency.[2,15,16] However, these techniques only move the fibrotic vocal fold to the midline and do not, in fact, correct the excavated vocal fold. In patients with post-cordectomy scarring, fibrosis of the neocord makes injection to the concavity more difficult, and the injected materials bulge in unwanted directions.

Minithyrotomy was originally designed for access to the sub-epithelial tissue planes of the vocal fold.[3] Because of the possibility of additional tissue injury and the technical difficulty of placing grafts, it is challenging to surgically repair subepithelial reinke's space. The minithyrotomy technique is more predictable than the conventional transoral method because it creates a 'tunnel pocket' space by scar lysis, followed by implantation of the fat block to recreate the viscoelastic properties of the vocal fold. Although vocal fold reconstruction using a minithyrotomy approach is at least theoretically ideal for post-cordectomy scarring, there is no animal-based evidence to determine whether the technique is safe and efficacious. Thus, animal models are essential to examine the mechanism and histological results of early and late minithyrotomy vocal fold reconstruction before clinical use.

Hyaluronic acid derivatives are the most common commercially available vocal fold injection material, and fat block implantation is known to absorbed less than a conventional fat injection.[6,17] In this study, a single block fat strip was used for the implant materials. This may obviate the need for fat processing and cell necrosis, which results in more volumetric maintenance than conventional fat injection.[18] We doubted whether single fat block implantation would improve the symmetry and viscoelastic properties of the scarred vocal folds as well as repair volume.[6]

In this study, the MT group and HA group had more volume than the CT group. However, only the MT group showed a statistically significant difference, compared with the CT group at post-minithyrotomy 6 months ($P < 0.05$).

Another concern is whether minithyrotomy vocal fold reconstruction, particularly the surgical manipulation involved, aggravates vocal fold scarring. Thus, CD34 immunohistochemical staining, HA staining, and collagen density evaluation were used. In a scarred vocal fold, there is usually excessive collagen deposition and a decreased hyaluronic acid composition.[9,19] CD34 immunohistochemical staining was used to detect the neovascularization status, a factor known to favor chronicity of the inflammatory process.[6]

In this study, based on HA and collagen density and CD34 immunohistochemical staining, minithyrotomy vocal fold reconstruction did not intensify vocal fold scarring and inflammation. This indicates the usefulness of minithyrotomy vocal fold reconstruction using an autologous fat block implant to reconstruct post-cordectomy scars after resection of the vocalis muscle without causing additional damage.

Our findings suggest that minithyrotomy vocal fold reconstruction using an autologous fat block may be feasible in humans for the rehabilitation of post-cordectomy dysphonia. Because this technique is more effective method than conventional fat injection in terms of vocal fold medialization itself. There are several advantages of the minithyrotomy vocal fold reconstruction technique. First, creation of the ‘tunnel pocket’ space allows for lysis of fibrotic scars and precise placement of the implant where it is most needed. Second, autologous fat can be harvested and placed as a single block implant, which reduces absorption of the fat cells.[20] The result is more volumetric maintenance and increased viscoelasticity and stiffness of scarred vocal folds. However, being an open procedure and the need for external skin incisions are disadvantages of minithyrotomy.

Showing improvement in vocal fold bulkiness but not showing an improvement of viscoelasticity is a limitation of this study. The focus of future studies will be rheological studies that demonstrate restoration of the vibratory capability of reconstructed vocal folds and techniques for more precise detection, such as real-time PCR.

V. CONCLUSIONS

Minithyrotomy vocal fold reconstruction using an autologous fat block can restore the volume of a resected vocal fold without causing additional damage. It may be a good treatment option for post-cordectomy patients.

REFERENCES

1. Dailey SH, Ford CN. Surgical management of sulcus vocalis and vocal fold scarring. Otolaryngol Clin North Am 2006;39:23-42.
2. Zeitels SM. Optimizing voice after endoscopic partial laryngectomy. Otolaryngol Clin North Am 2004;37:627-36.
3. Gray SD, Bielamowicz SA, Titze IR, Dove H, Ludlow C. Experimental approaches to vocal fold alteration: introduction to the minithyrotomy. Ann Otol Rhinol Laryngol 1999;108:1-9.
4. Lee SW, Kim JW, Koh YW, Shim SS, Son YI. Comparative Analysis of Efficiency of Injection Laryngoplasty Technique for with or without Neck Treatment Patients: A Transcartilaginous Approach Versus the Cricothyroid Approach. Clin Exp Otorhinolaryngol 2010;3:37-41.
5. Paniello RC, Sulica L, Khosla SM, Smith ME. Clinical experience with Gray's minithyrotomy procedure. Ann Otol Rhinol Laryngol 2008;117:437-42.
6. Duprat Ade C, Costa HO, Lancelotti C, Ribeiro de Almeida R, Caron R. Histologic behavior of the inflammatory process in autologous fat implantation in rabbit vocal folds. Ann Otol Rhinol Laryngol 2004;113:636-40.
7. Branski RC, Rosen CA, Verdolini K, Hebda PA. Acute vocal fold wound healing in a rabbit model. Ann Otol Rhinol Laryngol 2005;114:19-24.
8. Tateya T, Tateya I, Sohn JH, Bless DM. Histologic characterization of rat vocal fold scarring. Ann Otol Rhinol Laryngol 2005;114:183-91.
9. Rousseau B, Hirano S, Scheidt TD, Welham NV, Thibeault SL, Chan RW, et al. Characterization of vocal fold scarring in a canine model. Laryngoscope 2003;113:620-7.
10. Kishimoto Y, Hirano S, Kitani Y, Suehiro A, Umeda H, Tateya I, et al. Chronic vocal fold scar restoration with hepatocyte growth factor

hydrogel. Laryngoscope 2010;120:108-13.
11. Catten M, Gray SD, Hammond TH, Zhou R, Hammond E. Analysis of cellular location and concentration in vocal fold lamina propria. Otolaryngol Head Neck Surg 1998;118:663-7.
12. Hammond TH, Gray SD, Butler J, Zhou R, Hammond E. Age- and gender-related elastin distribution changes in human vocal folds. Otolaryngol Head Neck Surg 1998;119:314-22.
13. Hirano S, Nagai H, Tateya I, Tateya T, Ford CN, Bless DM. Regeneration of aged vocal folds with basic fibroblast growth factor in a rat model: a preliminary report. Ann Otol Rhinol Laryngol 2005;114:304-8.
14. Park KT, Ahn Y, Kim KH, Kwon TK. Schwannoma mimicking laryngocele. Clin Exp Otorhinolaryngol 2010;3:166-71.
15. Kishimoto Y, Hirano S, Kojima T, Kanemaru S, Ito J. Implantation of an atelocollagen sheet for the treatment of vocal fold scarring and sulcus vocalis. Ann Otol Rhinol Laryngol 2009;118:613-20.
16. Park JH, Do NY, Cho SI, Choi JY. Granular cell tumor on larynx. Clin Exp Otorhinolaryngol 2010;3:52-5.
17. Lee SH, Kwon HJ, Choi HJ, Lee NH, Lee SJ, Jin SM. The Singer's Formant and Speaker's Ring Resonance: A Long-Term Average Spectrum Analysis. Clin Exp Otorhinolaryngol 2008;1:92-6.
18. Kononas TC, Bucky LP, Hurley C, May JW, Jr. The fate of suctioned and surgically removed fat after reimplantation for soft-tissue augmentation: a volumetric and histologic study in the rabbit. Plast Reconstr Surg 1993;91:763-8.
19. Tateya T, Tateya I, Bless DM. Immuno-scanning electron microscopy of collagen types I and III in human vocal fold lamina propria. Ann Otol Rhinol Laryngol 2007;116:156-9.
20. Woo P, Rahbar R, Wang Z. Fat implantation into Reinke's space: a

histologic and stroboscopic study in the canine. Ann Otol Rhinol Laryngol 1999;108:738-44.

ABSTRACT (IN KOREAN)

토끼 동물 모델에서 자가지방을 이용한 minithyrotomy 성대 재건술의 유용성

<지도교수 최은창>

연세대학교 대학원 의학과

이승원

연구 목적: 성대암으로 성대 근육을 포함하는 성대절제술 받는 경우 수술 후 재생된 성대는 오목하고 섬유화 되어, 발성 시에 정상적인 성대접촉이 불가능하여 애성을 유발하게 된다. 현재의 음성 재활수술방법은 오목한 성대를 정상적인 성대 모양으로 재건하는 것이 불가능 하였다. 이에 저자는 섬유화된 성대를 미리 박리하여 만든 이식물 삽입 공간에 자가지방 이식 (autologous single fat block)을 시행하는 토끼 minithyrotomy 성대재건술 실험을 통하여 성대 절제술 후 애성을 호소하는 환자에게 새로운 음성 재활 수술법을 확립하고자 한다.

연구 방법: 25 마리의 2.5-3.0kg 토끼를 대상으로 내시경하에서 성대를 관찰하면서 전기소작기(bovie electrocautery, Conmed, Utica, NY, USA)를 이용하여 편측 성대절제술을 시행한다. 25 마리의 편측 성대절제술을 시행 받은 토끼 중에 실험군은 자가지방 성대재건술을 시행 받은 10 마리(single fat block minithyrotomy vocal fold reconstruction, MT group)와

히알루론산(hyaluronic acid) 성대재건술을 시행 받은 5 마리(HA group)로 구성되었다. 나머지 10 마리는 실험군(CT group)으로 편측 성대절제술을 시행 후 술 후 4 개월, 9 개월째에 성대를 획득하였다. Minithyrotomy 성대재건술은 성대절제술 후 3 개월째에 시행하였고, MT group 은 minithyrotomy 성대재건술 후 1 개월, 6 개월째에 5 마리 토끼 성대를 획득하였고, HA group 은 minithyrotomy 성대재건술 후 3 개월째에 성대를 획득하였다.

Image J image analysis software (Image J 1.43u National Institutes of Health, Bethesda, MD) 와 Adobe Photo shop Image Analysis Software (Adobe Systems Inc, San Jose, CA) 을 이용하여 hematoxylin eosin stain (H-E stain) 상에서 MT group, HA group, CT group 의 성대 면적 (total square amounts of vocal fold)을 정량 분석 한다. masson trichrome stain 하에서 MT group, HA group, CT group 간의 콜라겐 밀도(collagen density)를 비교 측정하고, alcian blue stain 하에서는 히알루론산의 밀도를 비교 분석한다. CD34 면역화학조직검사(immunohistochemical stain)을 시행하여 미세혈관밀도 (microvascular density)를 각 군간에 비교 측정하였다

결과: MT group은 CT group에 비하여 자가지방 성대재건술 후 1개월째에 성대면적이 통계적으로 유의하게 높았으며 이는 술 후 6개월까지 유지 되었다. ($P < 0.05$) 하지만, 두군 간의 성대 콜라겐 밀도, 히알루론산 밀도, 신생혈관 정도는 유의한 차이를 보이지 않았다. ($P > 0.05$) HA group과 CT group간에는 성대면적, 콜라겐, 히알루론산 밀도 및 신생혈관 정도는 통계적으로 유의한 차이를 보이지 않았다.

결론: 토끼에서 자가지방을 이용한 minithyrotomy 성대 재건술은 성대 용적을 술 후 6개월까지 유지하면서 성대 반흔을 악화시키지 않는 소견을 보였다. 기존의 지방 주입술 (fat injection)보다 효과적으로

성대를 내전시키므로(medial augmentation) 이 술식은 성대절제술을 시행 받은 환자에게 새로운 음성 재활 수술로 적용할 수 있을 것으로 사료된다.

핵심 되는 말: 성대, 결손, 재건,