

Serial Changes of MR Images Throughout the Stages of Infection of Spondylodiscitis

Tae-Hyung Kwon, M.D.,¹ Zun-Zae Shin, M.D.,¹ Sung-Uk Kuh, M.D.,¹
Young-Sul Yoon, M.D.,¹ Yong-Eun Cho, M.D.,¹ Young-Soo Kim, M.D.²

Department of Neurosurgery, ¹Yonsei University College of Medicine, Yongdong Severance Hospital, Seoul, Korea

Department of Neurosurgery,² Kwanghye Spine Center, Seoul, Korea

Objective : Spondylodiscitis has been diagnosed by clinical, radiological and laboratory methods. MR imaging is well known as an excellent diagnostic tool for spondylodiscitis. However, the changes in MR images throughout the treatment process has not been studied. Thus we have analyzed the serial changes of MR images throughout the stages of infection.

Methods : Ten patients were selected for retrospective reviewed who had been treated at our institute for infectious spondylodiscitis between 2000 and 2005. These patients had been followed-up at least six months and had taken more than a couple of series of MR scans. We classified the MR images into four groups according to the stages of treatment for the infection and compared them to the clinical and laboratory findings.

Results : MR image signals changed minimally or appeared to be normal in the early stages. The progression of spondylodiscitis was characterized by a low T1 WI signal and a high T2 WI signal in disc and vertebral body. The signal changes of the MR images were then propagated and the endplate was destructed. During the treatment, the destructed endplate became stabilized and the signal intensity of both T1 and T2 WI were fixed to low-or iso-intensity

Conclusion : We can determine the serial signal changes based on MR images according to the treatment of spondylodiscitis. We can therefore determine the status of the infection and the stage of treatment, as well as the diagnosis of spondylodiscitis using serial MR images.

KEY WORDS : Spondylodiscitis · MR image · Infection · C-reactive protein.

Introduction

Spondylodiscitis has been diagnosed by clinical and radiological findings, as well as by laboratory methods such as tests measuring the erythrocyte sedimentation rate(ESR) and for C-reactive protein(CRP). The symptoms of patients with spinal infection may vary considerably and are sometimes nonspecific³⁾. Early diagnosis of spondylodiscitis is essential to prevent serious morbidity and mortality, but this is sometimes difficult and causes treatment to be delayed. Imaging studies are usually used for the confirmation and localization of spinal infections. Magnetic resonance(MR) imaging is especially well known as an excellent diagnostic tool for spondylodiscitis, as it is 93% more sensitive and 97% more specific than the methods of computed tomographic scanning, plain radiographs, and bone scans³⁾.

The incidence of spondylodiscitis has recently increased and it may be related to common percutaneous procedures, such as the pain-block procedure, performed to help patients experiencing back pain. Spondylodiscitis is usually difficult to treat and it may also leave the patient with sequelae, pain, or deformities even if treated well. The MR imaging is now more widely used for the initial diagnosis and is often used to confirm the effectiveness of treatment.

It can be difficult to determine whether the infection has been treated effectively or not, especially when there is a discrepancy between the laboratory findings and the MR findings. The change in MR images throughout the progression of spondylodiscitis has not been reported. This is why we have analyzed the serial changes of MR findings according to the progression of spondylodiscitis and stage of the treatment process.

• Received : May 29, 2006 • Accepted : August 22, 2006

• Address for reprints : Sung-Uk Kuh, M.D., Department of Neurosurgery, Yonsei University College of Medicine, Yongdong Severance Hospital, 146-92 Dogok-dong, Gangnam-gu, Seoul 135-270, Korea Tel : +82-2-2019-3404, Fax : +82-2-3461-9229, E-mail : kuhsu@yumc.yonsei.ac.kr

Materials and Methods

Among the patients with spontaneous spondylodiscitis who were treated at our institute as of March 2000, we selected ten patients who had more than two MR imagings not related to tuberculosis spondylitis or to a postoperative infection and who were followed up for more than six months. These patients were retrospectively reviewed. The average age of the patients at the time of diagnosis was 61.3 years (45~81 years). There were four men and six women. The patients had MR images including T1 weighted images(WI), T2 WI,

Table 1. Stage of spondylodiscitis according to treatment

| Stage of infection | Laboratory and Clinical finding |
|--------------------|---|
| A1 | Initial state of infection |
| A2 | Early state of infection (ESR : > 40mm/hr, CRP : > 20mg/dL, VAS : 8-10) |
| B | Partially treated state of infection (ESR : < 40mm/hr, CRP : 5 < < 20mg/dL, VAS : 4-7) |
| C | Completely treated state of infection (ESR : < 20mm/hr, CRP : < 5mg/dL, VAS : 2-3) |

Table 2. Demographics of patients

| Case | Sex /Age | Level | Symptom | Treatment | Culture | Antibiotics | Result |
|------|----------|---------|------------|--|---------------|-----------------------------|-----------|
| 1 | M/63 | L3/4 | LBP | Conservative care | No growth | IV : 6 wks Oral : 16 wks | Excellent |
| 2 | F/45 | L4/5 | LBP, RLP | Discectomy L4/5 Wound irrigation and catheter insertion (4wks) | MRSA | IV : 8 wks Oral : 16 wks | Good |
| 3 | F/68 | L2/3/4 | LBP | Conservative care | No growth | IV : 2 wks Oral : 8 wks | Excellent |
| 4 | M/81 | L3/4/5 | LBP | Discectomy L3/4, L4/5 Wound irrigation and catheter insertion (1wk) | No growth | IV : 2 wks Oral : 4 wks | Good |
| 5 | M/47 | L4/5 | Fever, LBP | ALIF L4/5 Wound irrigation and catheter insertion (3wks) | No growth | IV : 8 wks Oral : 4 wks | Excellent |
| 6 | F/64 | L1/2 | LBP | Discectomy L1/2 Wound irrigation and catheter insertion (4wks) | No growth | IV : 6 wks Oral : 12 wks | Good |
| 7 | F/57 | L4/5 | LBP | Conservative care | No growth | IV : 5 wks Oral : 8 wks | Good |
| 8 | M/49 | L2/3 | LBP | Conservative care | No growth | IV : 9 wks Oral : 4 wks | Excellent |
| 9 | F/65 | L4/5/S1 | LBP | Discectomy L4/5 Conservative care | S. marcescens | IV : 8 wks Oral : 8 wks | Good |
| 10 | F/45 | L4/5/S1 | LBP | Conservative care | No growth | IV : 3 wks Oral : 8 wks | Good |

M : male, F : female, LBP : low back pain, RLP : right leg pain, ALIF : anterior lumbar interbody fusion, MRSA : methicillin resistant *Staphylococcus aureus*, S. marcescens : *Serratia marcescens*, IV : intravenous

and gadolinium(Gd) enhanced images taken.

Four patients underwent surgery with an open surgical drainage and irrigation and one patient had a discectomy. All patients were first treated with intravenous antibiotics (2~8 weeks) and then with oral antibiotic treatments (4~16 weeks) according to the clinical and laboratory findings.

The clinical symptoms and laboratory parameters, including the ESR and CRP levels, were checked twice a week after the infection was confirmed.

To determine a patient's stage in the infection treatment process, we classified with four groups (A1 : initial state of infection, A2 : early state of infection, B : partially treated infection, C : completely treated infection) according to clinical and laboratory findings (Table 1). The MR images were also analyzed for the signal changes of T1 WI, T2 WI, and Gd enhanced images according to stage of the infection treatment process.

Results

Clinical findings

All patients complained of low back pain at the initial time of spondylodiscitis. Only one of the ten patients reported also having radiating leg pain and another patient had a febrile condition. In some of the patients, the infections were masked by pre-existing chronic back pain (Table 2).

Microbiology

Blood cultures were carried out for all ten patients. Another culture of the intraoperative septic focus tissue was taken from the five patients who underwent operation. Only in two abscess tissue cultures could infectious agents be retrieved, which were methicillin resistant *Staphylococcus aureus*(MRSA) and *Serratia marcescens*. The remaining cultures yielded negative results.

Patient staging and MR findings

At the time of diagnosis, all patients belonged either to the infection stage A1, the initial state (3 patients), or to the infection stage A2, the early state (7 patients).

After intravenous antibiotics

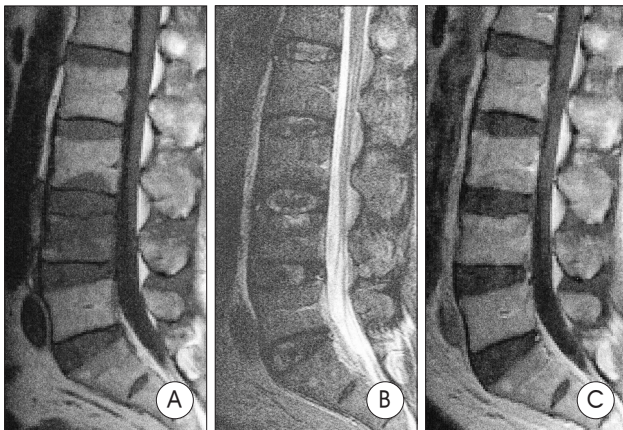


Fig. 1. The initial magnetic resonance images of patient No. 1 at stage A2. The images show low signal intensity in both the endplates and the vertebral body on T1 WI (A) and slightly high signal intensity on T2 WI (B). No enhancement of the lesion is seen (C).

Table 3. Individual magnetic resonance findings and staging

| Case | Stage (ESR/CRP) | | |
|------|-----------------|--------------------|--------------------|
| | 1st MR finding | 2nd MR finding | 3rd MR finding |
| 1 | A2 (59/9.5) | B (51/3.3); 4 wks | C (19/0/9); 17 wks |
| | -/0/NE | -/+E | 0/0/NE |
| 2 | A2 (51/41.9) | B (51/22.9); 2 wks | C (10/2.3); 16 wks |
| | -/0/NE | -/+E | -/0/NE |
| 3 | A2 (50/135) | B (51/2.3); 8 wks | |
| | -/+E | -/+NE | |
| 4 | A2 (58/82.2) | C (32/26); 24 wks | |
| | -/0/NE | 0/0/NE | |
| 5 | A1 | A2 (40/90.5) | C (18/0.7); 7 wks |
| | 0/0/NE | -/+* | -/+NE |
| 6 | A1 | A2 (56/9.4) | B (45/6.2); 8 wks |
| | -/0/* | -/+NE | -/+E |
| 7 | A1 (28/11.4) | B (9/0.9); 4 wks | |
| | -/0/NE | -/+E | |
| 8 | A2 (65/20.0) | B (51/2.0); 6 wks | |
| | -/+E | -/+E | |
| 9 | A2 (56/235.9) | B (44/1.1); 8 wks | C (34/0.9); 21 wks |
| | -/0/NE | -/+NE | 0/0/E |
| 10 | A2 (275/2.5) | B (66/4.9); 3 wks | |
| | -/+E | -/+E | |

Time : period since diagnosis(weeks). MR finding : T1 WI / T2 WI / Gd enhancement.
 + : high signal intensity, - : low signal intensity, 0 : isosignal intensity. E : enhanced, NE : not enhanced. * : no evaluation of Gd enhancement

treatment, the patients usually progressed to infection stage B, the partially treated stage. Over seven weeks later, these patients then progressed to the infection stage C, which was defined as the completely treated state (Table 3).

The MR images taken during stage B were worse than at stage A2, even in the patients that had improved clinical or laboratory findings. More than four months after the antibiotic therapy, the MR images began to indicate that the healing process of stage C had begun in patients No. 1, 2, and 4. Patient No. 5 still had prominent inflammation throughout stage C.

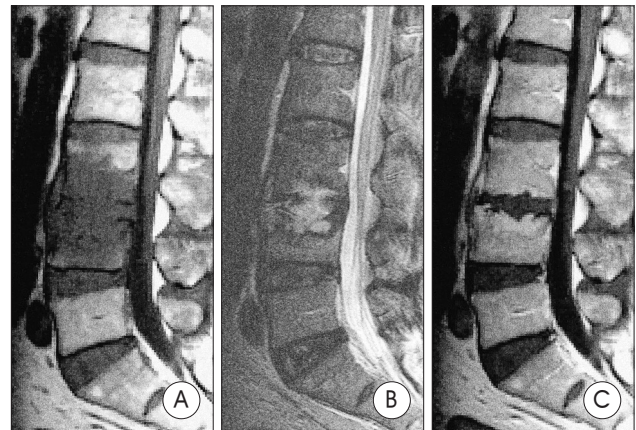


Fig. 2. The magnetic resonance images of patient No. 1 at the partially treated stage B. One month after intravenous antibiotic treatments, the low signal intensity on T1 WI (A) and the high signal intensity on T2 WI (B) are shown to exhibit extensive propagation and destruction of the endplates. This time, the lesion is enhanced with gadolinium (C).

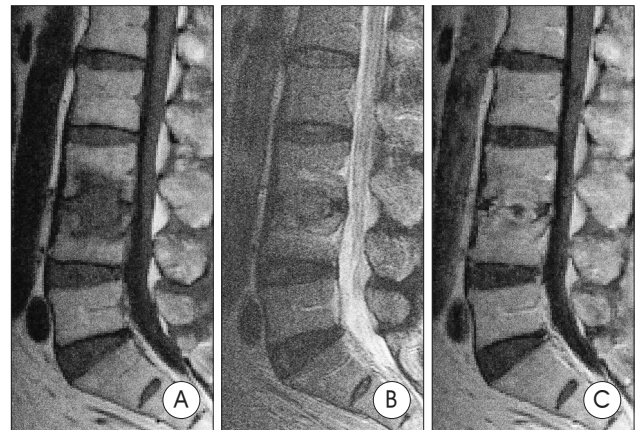


Fig. 3. The magnetic resonance(MR) images of patient No. 1 at stage C after complete treatment. Four months after intravenous antibiotic treatments, the low signal intensity on T1 WI (A) and the high signal intensity on T2 WI (B) are reduced and stabilized. The gadolinium-enhanced MR images (C) are also enhanced especially in the involved disc space.

Patients No. 5 and 6 were not initially diagnosed as having a spinal infection. Patient No. 5 had intense progressive back pain and developed fevers, however, it was too hard to see evidence of infection with only the MR images at that time. We checked the MR images two weeks later and the patient was finally diagnosed as having a spinal infection. Patient No. 6 was conservatively treated for two months in another hospital, but spondylodiscitis was not confirmed at that time.

During the early stages of spondylodiscitis, changes of the MR image signal were minimal or appeared normal. As the spinal infection progressed, the low signal of T1 WI in the vertebral body and the high signal of T2 WI in the bone and disc became evident. After several weeks of antibiotic therapy, lasting up to eight weeks in this study, the low signal of T1 WI in the vertebral body and high signal of T2 WI in the bone and disc remained the same and the Gd enhancement

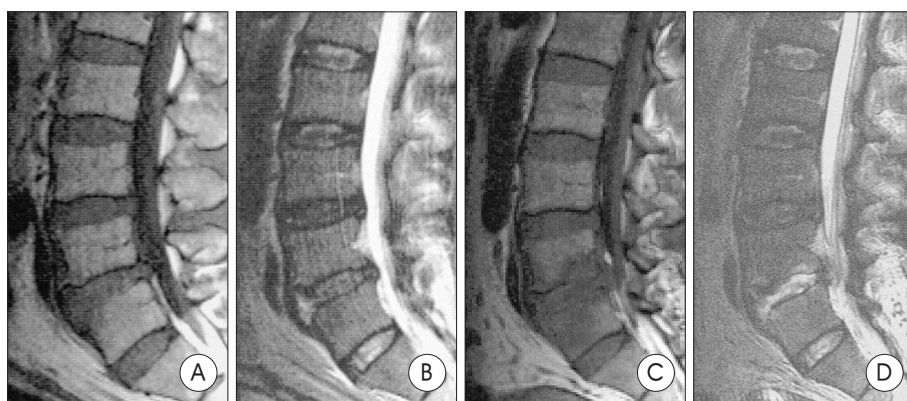


Fig. 4. A, B : The initial magnetic resonance(MR) images of patient No. 5 at stage A1. There is no definite bony or signal change on the endplates and vertebral body, except for a slight signal difference in the anterior disc space on T2 WI. Definite diagnosis of the infection cannot be made by images at this stage. C, D : MR images of patient No. 5 at stage A2 two weeks later. The images have changed to a low signal on T1 WI (C) and a definite high signal intensity on T2 WI (D).

Table 4. MR findings according to infection stage

| | A1 : Initial state | | A2 : Early state | | B : Partially treated state | | C : Completely treated state | |
|----------|--------------------|-------------------|--------------------------|-------------------|-----------------------------|-------------|------------------------------|-----------------------|
| | Bone | Disc | Bone | Disc | Bone | Disc | Bone | Disc |
| T1 WI | low signal | isosignal | low signal | isosignal | low signal | low signal | low signal | low signal |
| T2 WI | isosignal | high or isosignal | isosignal or high signal | high or isosignal | high signal | high signal | low, iso, high signal | low, iso, high signal |
| Gd | No | No | No | No | enhance | enhance | enhance | enhance |
| -enhance | enhance | enhance | enhance | enhance | | | | |

progressed. Finally, the intensity of signal changes decreased throughout the process of infection control (Table 4).

Discussion

The evaluation of spinal infections has continually evolved as new imaging techniques have been introduced. MR imaging is now the modality of choice for the evaluation of potential spinal infection¹³⁾. Plain films, radionuclide scans, and computed tomographic scans can yield false-negative results. MR imaging has many advantages, such as the capability of multiplanar imaging, direct evaluation of the bone marrow, and simultaneous visualization of the neural structures⁹⁾.

The principal disadvantage of MR imaging is the tendency to overestimate bone involvement. However, when used in conjunction with plain radiographs and CT scans, MR imaging is an excellent tool for diagnosis and determining the extent of disease.

Several MR imaging patterns and signal intensity alterations have been described as indicative of spinal infection, including decreased disc height, hypointensity of the disc on T1 WI, hyperintensity of the disc on T2 WI and on Gd enhancement, effacement of the nuclear cleft, and erosion of the

vertebral endplates on T1 WI^{7,9,10,15)}. As spondylodiscitis progresses, it is characterized by a low signal of the T1 WI and high signal of the T2 WI in both the disc and vertebral body on contrast enhanced images, due to the inflammatory reaction in the marrow. Subsequently, MR signal changes such as the propagation of a low T1 WI signal and a high T2 WI signal occur, and also the endplate starts to destruct.

Usually, the disc height is lost with time. The healing process can be monitored by MR imaging, because the T1 signal returns to normal as the inflammatory cells are replaced by fat cells in the affected vertebrae^{3,12,14,15)}. MR images sometimes worsen even though the clinical and laboratory findings improve.

We suggest classifying the stages of infectious spondylitis by the progress of the infection and the healing process. As shown in Table 1, this classification depends mainly on clinical symptoms, such as the degree of pain, and laboratory parameters, such as the ESR and CRP results. Stage A1 is the initial state of infection and patients classified in this stage are asymptomatic or have mild back pain. The inflammatory markers of these patients are elevated mildly. Stage A2 is the early state of infection and patients in this stage complain of moderate or severe back pain and their inflammatory parameters are elevated. Stage B is the partially treated state of infection and stage C is the state when the infection has been completely treated.

The ability to diagnosis spondylodiscitis early on, more specifically at stage A1, may be difficult with only MR images. The changes are due to the fissuring of the cartilaginous endplate and increased vascularity within the subchondral bone marrow. Modic changes are identified in 20~50% of patients, with the incidence increasing with age. Inflammation in the subchondral bone adjacent to the endplate results in reduced signal intensity of the T1 weighted MR sequences and increased signal intensity of the T2 weighted MR sequences, which is equivalent to a Type 1 Modic change¹⁾.

Initial MR images early on in the infection may show normal results or Modic type I degeneration : low signal intensity in the vertebral endplates of T1 WI and increased signal in-

tensity of T2 WI¹⁾. It is particularly more difficult to diagnose the initial state of infection in patients having back pain caused by other spine diseases such as spinal stenosis, disc herniations, or degenerative disc diseases.

The average delay in diagnosis of pyogenic vertebral infection was reported in several studies as being two to six months after symptoms began^{2,6,11,15)}. The nonspecific nature of laboratory and radiographic findings, as well as the ubiquitous nature of back pain, have made diagnosis difficult in most cases. On the other hand, the MR findings of pyogenic spondylitis were often characteristic and occurred early on in the disease^{1,3,7,12,15)}.

Patient No. 5 was suspicious of having spondylitis when first diagnosed. The infection became evident two weeks later by follow-up MR imaging and laboratory marker results (ESR 40mm/hr, CRP 90.5mg/dL). Patient No. 6 underwent MR imaging at the other hospital but the findings did not show a definite infection. Her symptoms were attributed to muscle strain or minor trauma, and so she was treated conservatively, but the pain persisted. Two months later, another MR scan was performed at our institute which definitely showed the cause of her pain to be spondylitis. She might have been at stage A1 when her first MR imaging was performed.

Therefore, patients with localized back pain that are at risk for developing such abscesses or have an increased level of ESR and/or neurologic deficit should have an MR scan performed as well as Gd enhancement. Repetitive examinations may be warranted if there is suspicion of an intraspinal infection on clinical grounds, even if the initial MR scans show no abnormality. Epidural fat in MR images may be the cause of the bright signal of T1 WI, which may obscure the contrast enhancement of the inflammatory tissue⁸⁾.

After two months of antibiotic therapy, patient No. 5 was classified as stage C. He was a 47-year-old man with an unremarkable medical history. He was relatively young in age and had no medical problems that might affect the rapid control of infection. His MR imaging after two months found an infection that was more prominent than before, even though the patient was classified as stage C. This suggests that two months is too short a time period to use MR images to monitor the beginning of the healing process. The healing process for patient No. 1, 2, and 4 took four months to be classified as stage C. We assume that the healing process would be evident in the MR images at least three months after the improvement of clinical and laboratory findings.

In the early stages of infection, the increased levels of CRP are more sensitive than the changes seen in MR images described above. The degree of improvement can also be revealed early on by the laboratory data on blood. The efficacy of conservative care may be estimated in individual cases by

pain relief, resolution of fever and leukocytosis, and a reduced ESR. Radiograph and MR imaging may be very slow or inconsistent in their resolution of infection-related abnormalities³⁾.

The extent of inflammatory changes is reflected indirectly by ESR levels as the change in the albumin-globulin ratio in plasma⁵⁾. Although the ESR generally does correlate well with response to treatment, its response rate alone during the first month was not a clear predictor of success⁴⁾. For this reason, care must be taken in the interpretation of a persistently elevated or even rising erythrocyte sedimentation rate as an isolated clinical result. Patients No. 3 and 5 took five and seven months, respectively, for their levels to return to the normal range.

White blood cell counts are unreliable for monitoring the treatment of an infection because they can vary extensively depending on nutritional and immunologic status⁵⁾.

The CRP is the most useful of the acute phase proteins, as its plasma concentration can increase within 24 to 48 hours from a normal resting state CRP concentration of about 1mg/L to several hundred times that upon injury to the tissue. These levels persist for the duration of the acute phase response and return to normal levels as the tissue is restored in both structure and function. The CRP levels correlated well with the changes in disease activity⁵⁾. However, the CRP levels are also sensitive to other infections, such as upper respiratory or urinary tract infections, so the white blood cell count and ESR should be considered as well.

Conclusion

We determined that the serial changes of MR images can be used to track the progression of spondylodiscitis and to monitor the treatment outcome. Misdiagnosis can occur during the early stages of infection because the image appears normal or as a Modic type I degeneration, and also during the early stages of treatment these images may appear exaggerated due to the change in fulminant inflammation.

We thus conclude that the serial evaluation of MR images could be helpful, but the images should be interpreted carefully for the diagnosis and management of the spinal infection.

References

1. Braithwaite I, White J, Saifuddin A, Renton P, Taylor BA : Vertebral end-plate (Modic) changes on lumbar spine MRI : correlation with pain reproduction at lumbar discography. *Eur Spine J* 7 : 363-368, 1998
2. Cahill DW, Love LC, Reichtine GR : Pyogenic osteomyelitis of the spine in the elderly. *J Neurosurg* 74 : 878-886, 1991
3. Carragee EJ : The clinical use of magnetic resonance imaging in pyogenic vertebral osteomyelitis. *Spine* 22 : 780-785, 1997
4. Carragee EJ, Kim D, van der Vlugt T, Vittum D : The Clinical Use of Erythrocyte Sedimentation Rate in Pyogenic Vertebral Osteomyelitis. *Spine* 22 : 2089-2093, 1997

5. Foglar C, Lindsey RW : C-reactive protein in orthopedics. *Orthopedics* 21 : 687-693, 1998
6. Heary RF, Hunt CD, Wolansky LJ : Rapid bony destruction with pyogenic vertebral osteomyelitis. *Surg Neurol* 41 : 34-39, 1994
7. Hwang GJ, Kuh SU, Chin DK, Cho YE, Kim YS : Management of Wound Infection after Lumbar Spine Fusion with Instruments. *J Korean Neurosurg Soc* 35 : 36-41, 2004
8. Kuker W, Mull M, Mayfrank L, Topper R, Thron A : Epidural spinal infection. Variability of clinical and magnetic resonance imaging findings. *Spine* 22 : 544-551, 1997
9. Ledermann HP, Schweitzer ME, Morrison WB, Carrino JA : MR Imaging Findings in Spinal Infections: rules or myths? *Radiology* 228 : 506-514, 2003
10. Maiuri F, Iaconetta G, Gallicchio B, Manto A, Briganti F : Spondylodiscitis : clinical and magnetic resonance diagnosis. *Spine* 22 : 1741-1746, 1997
11. Malawski S, Lukawski S : Pyogenic infection of the spine. *Clin Orthop* 272 : 58-66, 1991
12. Sharif H : MR in managing spine infections. *Am J Roentgenol* 158 : 133-145, 1992
13. Stabler A, Reiser MF : Imaging of spinal infection. *Radiol Clin North Am* 39 : 115-135, 2001
14. Szypryt EP, Hardy JG, Hinton CE, Worthington BS, Mulholland RC : A comparison between magnetic resonance imaging and scintigraphic bone imaging in the diagnosis of disc space infection in an animal model. *Spine* 13 : 1042-1048, 1988
15. Thrush A, Enzmann D : MR imaging of infectious spondylitis. *Am J Neuroradiol* 11 : 1171-1180, 1990

Commentary

Advanced spondylodiscitis is easily diagnosed by clinical symptoms, laboratory findings including elevated erythrocyte sedimentation rate(ESR) and C-reactive protein(CRP), and radiologic findings including MRI. But spondylodiscitis is usually difficult to treat and it may also leave the patient with

sequelae, pain, or deformities even if treated well. So early diagnosis is essential, however, is often beset with problems because of the lack of specific symptoms and nonspecific radiologic findings.

The authors suggested that even MR images the most sensitive and specific tool, appear normal or as a Modic type I degeneration during the early stages of spondylodiscitis, and made realize that serial evaluation of MR images are important tool especially in diagnosing the patients with backache unknown origin. And the authors also proved that the change in MR images is usually delayed rather than the change in clinical and laboratory findings in those suffering from spondylodiscitis.

But the only MR findings cannot become the guideline of treatment in spondylodiscitis, because that prominent inflammatory findings remain in MRI after complete treated state. Furthermore the results of this article were obtained from a small group. And the classification system of stage of infectious spondylodiscitis that the authors suggested only depend on degree of pain and laboratory findings. And So I think, if you analyze serial MR findings in more large population and integrate the result with the classification system, excellent clinical guidance for management of spondylodiscitis will be made.

Jin-Young Youm, M.D.
Department of Neurosurgery
Chungnam National University Hospital